

# *Technique of laparoscopic nephrectomy in a patient with previous urinary diversion*

Ivan Hsia, BSc, Anil Kapoor, MD

Department of Surgery (Urology), McMaster University, Hamilton, Ontario, Canada

---

HSIA I, KAPOOR A. Technique of laparoscopic nephrectomy in a patient with previous urinary diversion. *The Canadian Journal of Urology*. 2003;10(5):2017-2019.

*Laparoscopic nephrectomy is quickly becoming accepted as the standard treatment for small renal neoplasms and benign renal disease. The presence of an ileal conduit has been termed a relative contraindication to laparoscopic surgery. A 58-year old female presented with recurrent pyelonephritis and hydronephrosis of her left kidney. Surgical removal was necessary and we considered a transperitoneal laparoscopic nephrectomy*

*for her. The patient had an ileal conduit and it was because of this reason that only after careful consideration was it decided to attempt the surgery using the laparoscopic approach. We present our technique of transperitoneal laparoscopic nephrectomy in this patient with an ileal conduit and include technical suggestions that will help predict a successful outcome. The success of this case demonstrates that in certain circumstances, patients with urinary diversions can be offered laparoscopic nephrectomy and its benefits.*

**Key Words:** laparoscopy, radical nephrectomy, ileal conduit

---

## Introduction

Laparoscopic nephrectomy is quickly becoming accepted as the preferred surgical method of managing small renal neoplasms not amenable to partial nephrectomy. The laparoscopic method is associated with reduced morbidity and hospitalization time. The first laparoscopic radical

nephrectomy was performed in 1991 and since then comparative studies have confirmed the advantages of the laparoscopic approach versus the traditional open technique.<sup>1</sup> The laparoscopic approach has been demonstrated to have significant reductions in blood loss, hospital stay, pain medication requirements, and time to normal activity for patients.<sup>2</sup>

Construction of an ileal conduit is the most common urinary diversion procedure performed in North America.<sup>3</sup> A section of the ileum, usually the portion proximal to the ileocecal valve, is isolated from the rest of the alimentary tract. Once the continuity of the alimentary tract is reestablished, the isolated section of ileum has one end closed, ureters re-implanted, and an opening established on the

---

Accepted for publication August 2003

Address correspondence to Dr. Anil Kapoor, Assistant Professor, Department of Surgery (Urology), McMaster University, St. Joseph's Hospital, 50 Charlton Avenue East, Hamilton, Ontario, L8N 4A6 Canada

surface of the skin as a stoma. Urinary diversion has been a relative contraindication to transperitoneal laparoscopic surgery due to difficulty in creating pneumoperitoneum, surgical working space, and potential intraoperative damage to the diversion itself. A retroperitoneal approach would be the preferred laparoscopic method, but most urologists are not familiar with retroperitoneal laparoscopic surgery.

We present our technique of transperitoneal laparoscopic nephrectomy of a hydronephrotic, pyelonephritic kidney in a patient with an ileal conduit.

## Case and technique

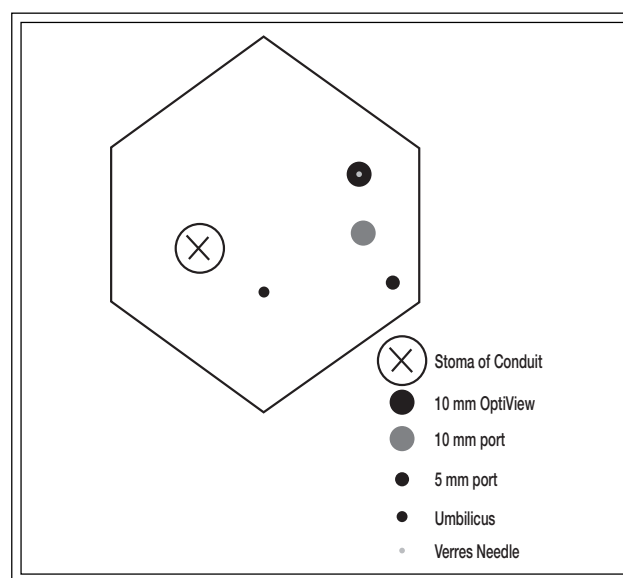
A 58-year old female was referred with recurrent pyelonephritis and hydronephrosis of her left kidney. In 1978, the patient had an ileal conduit constructed subsequent to radical cystectomy in treatment for bladder cancer. There were no infections until 1994 when the patient began to develop recurrent infections, hydronephrosis, and stricture in her left ureter. Initially, she was treated with ureteric dilatation and stent placement to relieve the obstruction and the infections. Infections persisted and the extensive stricture of the lower left ureter did not allow for further treatments with double J stents. Investigations were performed to assess whether the obstruction and infections had compromised the left kidney.

A CT Scan showed severe hydronephrosis on the left side. She was managed with an indwelling percutaneous nephrostomy tube for 2 years. Renal scan showed 38% function left kidney versus 62% function right kidney. She was referred to us for further management.

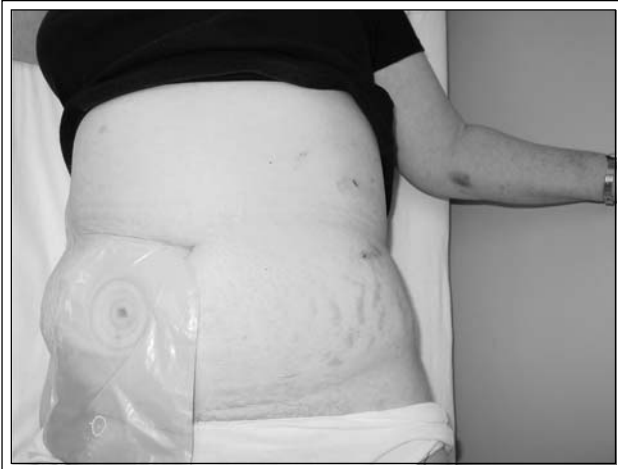The options were discussed with the patient, including open re-operative repair of distal left ureteric stricture, ongoing management with long-term nephrostomy tube, or ablation with laparoscopic nephrectomy. She elected to have a laparoscopic nephrectomy, choosing the surgery over continuing her long term management with the nephrostomy tube. The understanding that the laparoscopic surgery may need to be converted to an open procedure was discussed.

The patient was placed in the modified flank position and the abdomen was insufflated to an intraperitoneal pressure of 15 mmHg using a Verres Needle inserted in the left upper quadrant. For the initial entry into the abdomen we used a 10 mm OptiView visual trocar (®Ethicon) inserted in the left upper quadrant below the costal margin. On initial survey, multiple intra-abdominal adhesions were noted. Two further ports were placed into the left upper quadrant (one 5 mm port, one 10 mm port) under direct vision, in a clustered

position, avoiding the adhesions Figure 1. Compared to conventional laparoscopic nephrectomy, these working ports were placed directly in the left upper quadrant almost "on top" of the kidney. After, adhesions were directly taken down using the harmonic scalpel (®Ethicon). The ileal conduit was directly visualized and not violated. We then identified the left kidney with intense perinephric reaction from the longstanding nephrostomy tube. We dissected the white line of Toldt and the ureter over the psoas muscle. The ureter was quite dilated and was dissected to its insertion into the ileal conduit. We divided the ureter at this junction using the Endo GIA stapler (®Ethicon) leaving a small ureteric stump. The laparoscopic nephrectomy was then carried forward by identifying the gonadal vein and dividing it with surgical clips. The gonadal vein was tracked up to the renal vein, where the renal artery was identified posteriorly. The renal artery was clipped proximally and distally and then divided. The renal vein was divided using the Endo GIA stapler (®Ethicon). The adrenal vein and adrenal gland were dissected off the upper pole of the kidney and left in-situ with the patient. The entire kidney was then mobilized and freed from its perinephric attachments. An Endo Catch bag (®Auto Suture) was then inserted into the upper trocar port and the kidney inserted into it. The kidney was safely withdrawn from the port site with blunt morcellation monitored under direct laparoscopic vision. The port sites were closed using the Carter-Thomason Suture Closure device. The patient tolerated the procedure well



**Figure 1.** Laparoscopic port placement. The port sites were clustered over the left upper quadrant to avoid adhesions and to allow the pneumoperitoneum to create adequate working space.



**Figure 2.** Post-operative result (2 weeks).

with 150 cc of blood loss. The total operative time was 2.5 hours.

The post-operative course was uncomplicated. The patient remained in hospital 2 days and required minimal analgesia. Normal activity was resumed in 2 weeks. Final pathology of the left kidney revealed hydronephrosis and chronic inflammation of the renal pelvis and ureter. At 2 weeks follow-up her serum creatinine was 86 and her wounds healed. Figure 2

## Discussion

The increased applicability of the laparoscopic approach in surgery has been due to advances in technology (light sources, optics, insufflation devices, trocars, etc.) and surgical understanding of laparoscopic techniques learned through increased surgical experience. In the surgical disciplines, gynecology was the first to use laparoscopic techniques. General surgery then entered the fray, followed by urology. Initially, laparoscopy's application in urology was limited to evaluation of non-palpable testes in the abdomen. It was not until the late 1980's that more techniques were added to the repertoire of urologic laparoscopy with increased frequency. These techniques included pelvic lymph node dissection for the staging of urologic malignant tumours, varicocele ligation, bladder neck suspensions and laparoscopic nephrectomy.<sup>4</sup>

The first laparoscopic nephrectomy was performed in 1991 at Washington University. The approach has greatly benefited the patients, demonstrating significant reductions in blood loss, hospital stay, pain medication requirements, and convalescence. Nephrectomies performed using the laparoscopic approach are becoming the technique of choice if the option is available. Relative contraindications to laparoscopic

techniques are morbid obesity, extensive prior abdominal or pelvic surgery, pelvic fibrosis, organomegaly, ascites, pregnancy, hernia, and iliac or aortic aneurysm.<sup>5-9</sup> Ileal conduit urinary diversion has been viewed as a relative contraindication for the transperitoneal laparoscopic approach because of difficulties in creating surgical working space, maintaining the pneumoperitoneum, and the potential damage to the urinary diversion. In these cases, the retroperitoneal approach may be preferred, but most urologists are not familiar with retroperitoneal laparoscopic surgery. Also, the ureter travels intraperitoneally to the ileal conduit, potentially creating problems for the retroperitoneal laparoscopic approach. In performing a transperitoneal laparoscopic nephrectomy in a patient with an ileal conduit we have shown the technique to be viable. The key point of the technique is to cluster the port sites over the kidney in order to avoid adhesions thereby creating an adequate working space not tethered by the conduit. This differs from conventional laparoscopic nephrectomy in that the ports are placed almost "on top" of the kidney in the left upper quadrant.

Urinary diversions are considered relative contraindications to the laparoscopic approach for nephrectomy. We present our technique of laparoscopic nephrectomy on a patient with an ileal conduit and believe that in certain circumstances the transperitoneal laparoscopic approach is viable and beneficial. □

## References

1. Clayman RV, Kavoussi LR, Soper NJ, Dierks SM, Meretyk S, Darcy MD, Roemer FD, Pingleton ED, Thomson PG, Long SR. Laparoscopic nephrectomy: initial case report. *J Urol* 1991;146(2):278-282.
2. Dunn MD, Portis AJ, Shalhav AL, Elbahnasy AM, Heidorn C, McDougall EM, Clayman RV. Laparoscopic versus open radical nephrectomy: a 9-year experience. *J Urol* 2000;164(4):1153-1159.
3. Benson MC, Olsson CA. Urinary diversion. *Urol Clin NA* 1992;19(4):779-795.
4. Stanley KE, Winfield HN, Donovan JF. Urologic laparoscopy. *Surg Ann* 1994;26:67-88.
5. Pautler SE, Phillips JL, Walther MM. Assessment of risk for intraabdominal adhesions at laparoscopy for urological tumors. *J Urol* 2002;168(6):2391-2394.
6. Parsons JK, Jarrett TJ, Chow GK, Kavoussi LR. The effect of previous abdominal surgery on urological laparoscopy. *J Urol* 2002;168(6):2387-2390.
7. Kuo PC, Plotkin JS, Stevens S, Cribbs A, Johnson LB. Outcomes of laparoscopic donor nephrectomy in obese patients. *Transplantation* 2000;69(1):180-182.
8. Jacobs SC, Cho E, Dunkin BJ, Bartlett ST, Flowers JL, Jarrell B. Laparoscopic nephrectomy in the markedly obese living renal donor. *Urol* 2000;56(6):926-929.
9. Gill IS, Kerbl K, Meraney AM, Clayman RV. Basics of Laparoscopic Urologic Surgery. Walsh:Campbell's Urology 8<sup>th</sup> ed. Walsh PC. City:Elsevier Science;2002:3456-3459.