

---

# *Urological manifestations of BK polyomavirus in renal transplant recipients*

Chiu Yen M. Chang, MD,<sup>1</sup> Azim Gangji, MD,<sup>2</sup> Katherine Chorneyko, MD,<sup>3</sup>  
Anil Kapoor, MD<sup>1</sup>

<sup>1</sup>Division of Urology, Department of Surgery, McMaster University, Hamilton, Ontario, Canada

<sup>2</sup>Division of Nephrology, Department of Medicine, McMaster University, Hamilton, Ontario, Canada

<sup>3</sup>Department of Laboratory Medicine, McMaster University, Hamilton, Ontario, Canada

---

CHANG CYM, GANGJI A, CHORNEYKO K, KAPOOR A. Urological manifestations of BK polyomavirus in renal transplant recipients. *The Canadian Journal of Urology*. 2005;12(5):2829-2836.

**Objectives:** BK polyomavirus (BKV) disease in renal transplant recipients has become an increasingly problematic clinical entity. Complications of BKV disease lead to chronic allograft nephropathy and ultimately loss in greater than 50% of cases. We reviewed our experience with BKV disease over a 5-year period.

**Patients and methods:** We performed 155 cadaveric and 168 live-related transplants between January 2000 and June 2005. During this period, seven patients had biopsy-confirmed BKV disease, which compromised the renal function of six cadaveric and one live-related renal transplant recipients. BKV was suspected as a potential cause of renal function deterioration after eliminating other possibilities. BKV was then confirmed by detecting viral DNA in urine samples by polymerase chain reaction (PCR) and visualizing viral particles in allograft biopsies

by electron microscopy.

**Results:** The deterioration of allograft function in five renal transplant recipients was due to polyomavirus-associated nephropathy and two due to ureteric stenosis. Upon confirmation of BKV, overall immunosuppression was reduced or modified with follow-up of 5 to 44 months. However, additional rescue therapies were used to stabilize allograft function including ciprofloxacin, intravenous immunoglobulin, and leflunomide. One patient died and another lost his allograft due to non-compliance and reverted to hemodialysis, but renal function in the remaining five allografts has remained stable at higher serum creatinine levels.

**Conclusions:** The management of BKV disease in renal transplant recipients is not yet clearly defined. However, early recognition of urological sequelae and modification of immunosuppressive therapy are essential to ensure adequate long-term function of these allografts.

**Key Words:** BK polyomavirus, infection, renal transplantation

---

Accepted for publication September 2005

## Acknowledgement

Dr. Gangji holds a Research Fellowship from the Canadian Society of Nephrology/Kidney Foundation of Canada.

Address correspondence to Dr. Anil Kapoor, Surgical Director, Renal Transplantation, Division of Urology, Department of Surgery, McMaster University, St. Joseph's Hospital, 50 Charlton Avenue East, Hamilton, Ontario, L8N 4A6 Canada

## Background

BK polyomavirus (BKV) or polyomavirus hominis type 1 belongs to a family of unenveloped double-stranded DNA viruses that include polyomavirus hominis type 2 or JC virus and simian virus SV40. Primary BKV infection appears to occur during childhood and persists in a latent state primarily in the urogenital tract such that more than 80% of the general population has serological evidence of BKV.<sup>1</sup>

The transmission of this virus remains unclear, and reactivation requires immunosuppressed states as in HIV-1 infection, transplantation, and chemotherapy. Reactivation of BKV is one of the infectious complications of potent immunosuppression used for renal transplant recipients. Upon reactivation and replication, organ dysfunction may result leading to BKV disease<sup>2</sup> in organs such as kidney, ureter, bladder, central nervous system, and respiratory tract.<sup>3</sup> The estimated incidence of BK viruria in renal transplant recipients 1 year after transplantation is of the order of 30% - 35% based on prospective studies.<sup>4-6</sup>

Several urological complications of BKV are known in the setting of organ transplantation, such as polyomavirus-associated nephropathy (PVAN) in renal and cardiac transplantation,<sup>6,7</sup> ureteric stenosis in renal transplantation,<sup>8</sup> and hemorrhagic cystitis in bone marrow transplantation.<sup>9</sup> More recently there have been case reports associating BKV with renal adenocarcinoma<sup>10</sup> and bladder cancer,<sup>11</sup> but the mechanism of carcinogenesis remains unclear.<sup>12</sup> The prevalence of PVAN in renal transplantation ranges from 1% to 10%, and occurring mostly in the first year after transplantation leading to allograft failure in 10% to >80% of cases.<sup>13</sup> Unfortunately, the pathogenesis, risk factors, diagnosis, and treatment of PVAN remain uncertain.

Multiple risk factors have been associated with the development of PVAN. The major risk factor is intense immunosuppression, particularly with combination therapy consisting of three or four classes of drugs (calcineurin inhibitors, antimetabolites, mTOR inhibitors, and corticosteroids). More specifically, a combination of tacrolimus, mycophenolate mofetil (MMF) and corticosteroid has been associated with an increased risk.<sup>14</sup> Conversely, anti-lymphocyte preparations used for induction were not associated with PVAN,<sup>6,15</sup> but these preparations and the number of corticosteroid pulses used for acute rejection were associated with the subsequent development of the disease.<sup>6</sup> Other risk factors include increasing number of HLA mismatches and episodes of rejection,<sup>16</sup> older age, male sex,<sup>17</sup> BK-seronegative recipients, particularly pediatric patients,<sup>18</sup> and cytomegalovirus (CMV) co-infection.<sup>19</sup>

Despite these risk factors, the development of BKV disease is unclear as only a small number of immunosuppressed patients with BKV infection develop urological sequelae. Three prospective studies have demonstrated high incidences of BKV detected in urine in 30% - 57% and plasma in 11.5% - 29% of renal transplant recipients.<sup>4-6</sup> Bressollette-Bodin et al observed BKV replication as early as 3

months after transplantation; however, despite the high detection rate of BKV in urine and plasma, none of their patients developed PVAN.<sup>5</sup> Similarly, Brennan et al noted a high incidence of BK viruria and viremia, but they also noted that none of their patients developed PVAN.<sup>4</sup> In contrast, Hirsch et al reported 5 of 78 patients (6.4%) that developed PVAN at a median of 28 weeks after transplantation.<sup>6</sup> Based on these studies, it is important to note the identification of BKV in urine or plasma in the setting of allograft dysfunction is not sufficient to diagnose PVAN. Tissue biopsy with polyomavirus histopathological changes is the current gold standard for diagnosis of PVAN.<sup>20</sup> These changes can be confirmed by either immunofluorescence staining of viral antigens, in situ hybridization of viral gene sequences, or electron microscopy.<sup>21</sup> However, the main disadvantage of tissue biopsy is the possibility of sampling error given the focal nature of the disease.<sup>22</sup>

Current strategies to treat PVAN involve mainly reducing the immunosuppressive maintenance therapy, or employing agents such as quinolones, leflunomide, and low dose cidofovir. However, none of these strategies are specific for BKV and the risk of rejection is worsened by reducing immunosuppression. Leflunomide inhibits pyrimidine synthesis and has been approved in the United States by the Federal Drug Administration for rheumatoid arthritis. Cidofovir is a cytosine-phosphate analog approved for CMV retinitis in HIV-infected patients.

Despite improvements in immunosuppressant agents, chronic renal allograft nephropathy continues to be a significant deterrent of successful renal transplantation,<sup>23</sup> especially with the increasing incidence of BKV disease. Therefore, we reviewed our experience with BKV and its urological sequelae. We report seven cases of renal transplant recipients affected by BKV disease.

## Patients and methods

We performed 155 cadaveric and 168 live-related transplants between January 2000 and June 2005. During this period, seven kidney transplant recipients with BKV disease were confirmed by transplant biopsy, six cadaveric and one live-related. The age of three female and four male patients ranged from 38 to 74 years. The etiologies of chronic renal failure and end-stage renal disease were Wegner's granulomatosis, hereditary nephritis, hypertension, lupus nephritis, ANCA vasculitis, and unknown in two cases. Patients were

on dialysis for 2 to 8 years prior to kidney transplantation. Induction therapy was used in two cases because of African-Canadian race and practice pattern. The surgical aspect of the kidney transplants consisted of a standard Gibson incision in the lower quadrant of abdomen and the usual end-to-side arterial and venous anastomoses. The uretero-vesical anastomosis was formed using the Lich-Gregoir technique and protected with a ureteric stent for 2-4 weeks. Following transplantation all patients were placed on triple immunosuppressive maintenance therapy with tacrolimus (FK506), MMF, and corticosteroid. One patient received cyclosporine instead of tacrolimus. All patients were followed up routinely in the transplant clinic with blood work.

Dosages of immunosuppressive agents were adjusted regularly in order to maintain therapeutic drug levels and minimize side effects. Renal transplant ultrasound with colour Doppler and other imaging procedures were requested whenever there were concerns of urinary tract obstruction. All potential possibilities for allograft dysfunction were considered. Urine samples were analyzed for the presence of BK virus using polymerase chain reaction (PCR) and renal biopsies undertaken to differentiate acute rejection from PVAN. One renal pathologist (K.C.) analyzed the biopsy specimens for histopathological features of rejection versus viral involvement. If the urine tests were positive for BK virus then visualization of viral particles was done under electron microscopy.

TABLE 1

Patient	ESRD etiology	Dialysis	Transplant	Immuno-suppression	BK Diagnosis
<b>R.M.</b> 67 yo female	Lupus nephritis	None	Cadaveric Aug 23, 1999	ATG induction, tacrolimus, MMF, steroid	Urine PCR not done EM Oct 16, 2001 Cr 186 $\mu\text{mol/L}$
<b>F.R.</b> 74 yo male	ANCA vasculitis	HD 7 yrs	Cadaveric Feb 13, 2002	Tacrolimus, MMF, steroid	Urine PCR +BKV Dec 5, 2002 EM May 9, 2002 Cr 158 $\mu\text{mol/L}$
<b>J.R.</b> 48 yo female	Unknown	HD 7 yrs	Cadaveric Feb 18, 2002	Tacrolimus, MMF, steroid	Urine PCR +BKV Oct 1, 2004 EM Nov 24, 2004 Cr 143 $\mu\text{mol/L}$
<b>A.B.</b> 72 yo female	Wegner's granulomatosis	PD 5 yrs	Cadaveric Feb 23, 2003	Cyclosporine, MMF, steroid	Urine PCR +BKV Sept 29, 2003 Cr 230 $\mu\text{mol/L}$
<b>S.C.</b> 38 yo male	Unknown	HD 3 yrs	Cadaveric Aug 2003	Tacrolimus, MMF, steroid	Urine PCR +BKV Jan 5, 2005 Tubular damage and nuclear changes Jan 6, 2005 Cr 1302 $\mu\text{mol/L}$
<b>A.L.</b> 66 yo male	Hypertension	HD 2 yrs	Live related Nov 26, 2003	Tacrolimus, MMF, steroid	Urine PCR not done EM Jun 7, 2004 Cr 166 $\mu\text{mol/L}$
<b>A.T.</b> 39 yo male	Hereditary nephritis	HD 8 yrs	Cadaveric Mar 3, 2004	ATG induction, tacrolimus, MMF, steroid	Urine PCR + BKV Oct 6, 2004 EM Sept 21, 2004 Cr 266 $\mu\text{mol/L}$

PD – peritoneal dialysis, HD – hemodialysis, MMF – mycophenolate mofetil, CNI – calcineurin inhibitor, IVIG

## Results

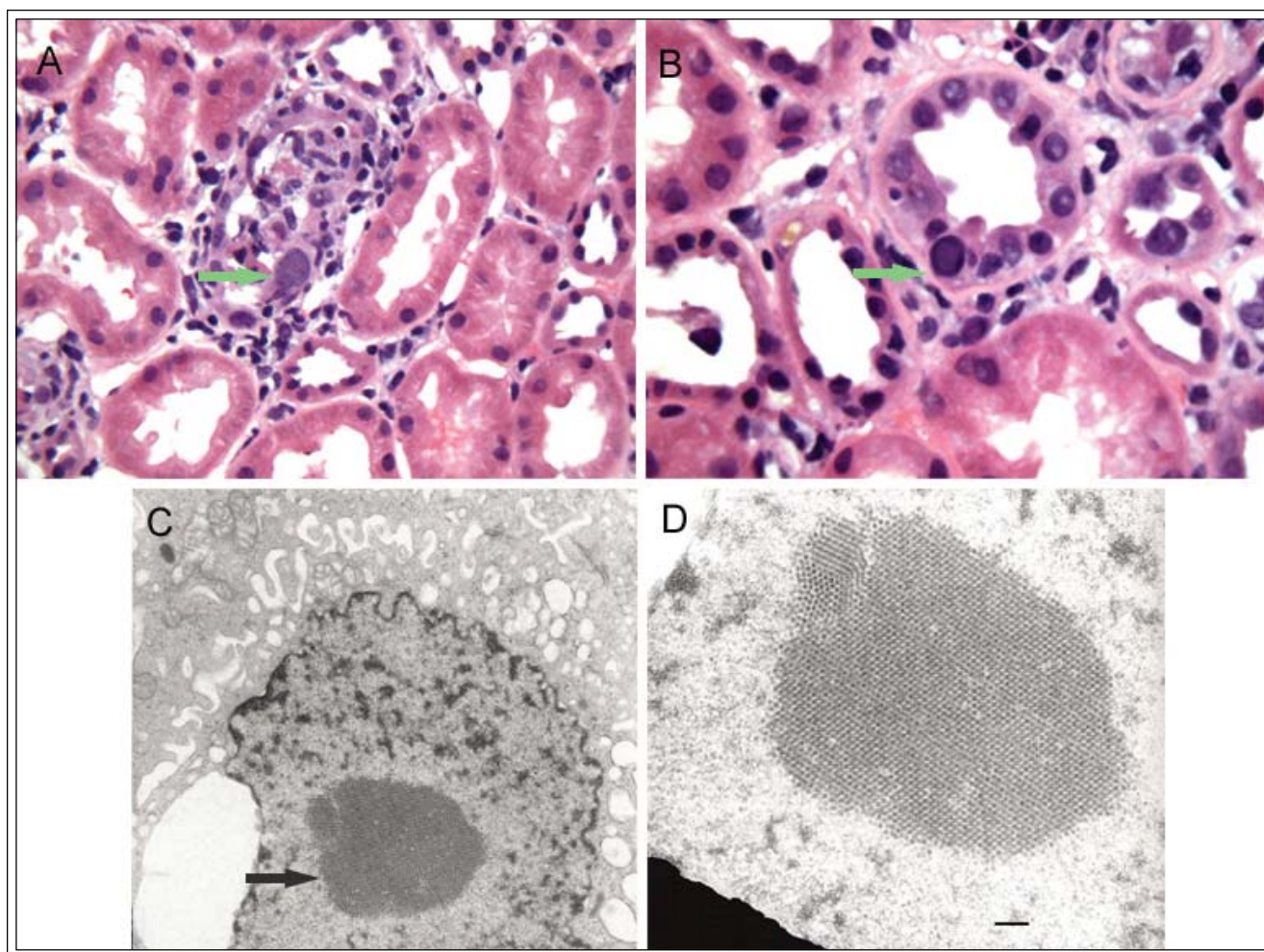
The follow-up of kidney transplant recipients diagnosed with deterioration of renal allograft function due to BKV disease ranges from 5 to 44 months as detailed in Table 1. The allografts of five patients were affected by PVAN and two by ureteric stenosis. Figure 1 shows representative histopathological features of PVAN. All patients were initially managed by gradual reduction of immunosuppression.

Patient A.T. developed delayed graft function and possible haemolytic uremic syndrome following transplantation, but this resolved without a change in therapeutic management. However, 6 months after transplantation this patient had

elevated serum creatinine requiring transplant biopsy. On the biopsy there was electron microscopy evidence of BK viral particles. MMF was gradually discontinued without any significant success, and so tacrolimus was also gradually discontinued. In the mean time the patient was also tried on ciprofloxacin without success. Peak serum creatinine was 341  $\mu\text{mol/L}$  and this has now stabilized in the proximity of 285  $\mu\text{mol/L}$  with leflunomide. Patient J.R.'s allograft deteriorated 20 months after transplantation due to PVAN. Despite gradual discontinuation of MMF, she had persistent allograft dysfunction. Ciprofloxacin and intravenous immunoglobulin was then tried without success. Currently, her allograft function has stabilized with leflunomide at a serum

TABLE 1

Treatment	Current status	Comments
Reduce MMF, reduce tacrolimus and switched to cyclosporine	Cr 169 $\mu\text{mol/L}$	
Reduce MMF and switched to azathioprine, reduce tacrolimus	Died Oct 2003	Delayed graft function, CNI nephropathy, recurrent episodes of rejection
Reduce and d/c MMF, ciprofloxacin, IVIG, leflunomide	Cr 278 $\mu\text{mol/L}$	Right RCC nephrectomy, 1995
Reduce MMF, ciprofloxacin, leflunomide	Cr 131 $\mu\text{mol/L}$ with stent	Proximal ureteric stenosis Sept 4, 2003 Lymphocele marsupialized Jan 05, 2004
None	Graft failure due to non-compliance Apr 2005	8-10 cm ureteric stenosis
Reduce MMF, reduce tacrolimus and switched to cyclosporine	Cr 138 $\mu\text{mol/L}$	Banff I rejection responsive to steroid Dec 2003
Reduce and d/c MMF, reduce and d/c tacrolimus, ciprofloxacin, leflunomide	Cr 286 $\mu\text{mol/L}$	Concerns about delayed graft function, and HUS
– intravenous immunoglobulin, EM – electron microscopy confirmation of BKV, HUS – hemolytic uremic syndrome		



**Figure 1.** Light and electron microscopy of renal allograft biopsy.

**A.** Arrow points to a tubule which is infiltrated by lymphocytes. One of the tubular epithelial cells has an enlarged nucleus. There is a mild lymphocytic interstitial infiltrate; however, the adjacent tubules are negative for tubulitis. (H&E, 250X).

**B.** Arrow points to a cell with enlarged, hyperchromatic nucleus with an intranuclear inclusion. (H&E, 400X).

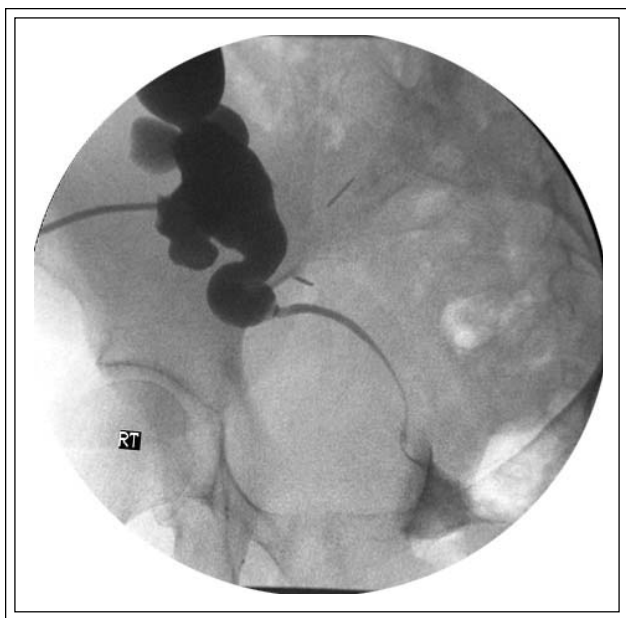
**C.** Arrow points to a tubular epithelial cell containing an intranuclear array of viral particles (electron microscopy, 40,000X).

**D.** Electron micrograph at a higher magnification showing the viral particles that measure approximately 40 nm. Bar represents 200 nm.

creatinine level of 278  $\mu\text{mol/L}$ . Patient A.L. experienced a mild episode of rejection 1 month after transplantation. This rejection was responsive to pulse steroids. However, 6 months after transplantation, there was evidence of BK viral particles on renal biopsy. His allograft function has stabilized with reduction of MMF and switching tacrolimus to cyclosporine. Patient R.M. had evidence of BK viral particles on transplant biopsy 21 months after her transplant. Her peak serum creatinine was 295  $\mu\text{mol/L}$ , and similar to A.L., her allograft function has stabilized with reduction of

MMF and switching tacrolimus to cyclosporine. The allograft of F.R. developed several complications including delayed graft function requiring 5 days of ATG therapy, tacrolimus-induced nephropathy, and recurrent episodes of acute rejection. In addition, 3 months post-transplantation there was evidence of PVAN on electron micrographs. Despite modification of immunosuppressive therapy, his peak serum creatinine was 278  $\mu\text{mol/L}$ . He unfortunately died 3 months later from a cardiac event.

Patient A.B. showed allograft deterioration 7



**Figure 2.** Anterograde nephrostogram demonstrating proximal ureteric stenosis of the renal allograft.

months after her transplant. This was first attributed to both a post-transplant lymphocele as well as a proximal ureteric stenosis, Figure 2. However, urine test revealed evidence of BKV. She was managed by balloon dilatation and ureteric stenting, as well as laparoscopic marsupialization of the transplant lymphocele. Despite reduction of MMF and treatment with ciprofloxacin, there was no significant improvement in allograft function. Eventually, her allograft function stabilized with leflunomide. Ureteric stent was removed 3 months later with subsequent recurrence of transplant ureteric stricture requiring long-term ureteric stenting with periodic changes. The patient deferred definitive surgical correction. Patient S.C. presented 17 months after transplantation with gradual decrease in allograft function and two episodes of acute rejection due to non-compliance. Urine test for BKV was performed after repeated hospitalizations for renal failure and returned positive. Anterograde nephrostogram demonstrated evidence of obstruction due to long ureteric stenosis. The function of the allograft was not salvageable despite nephrostomy tube decompression, and he ultimately reverted to hemodialysis.

## Discussion

Chronic allograft dysfunction due to BKV disease is a significant concern in renal transplantation. Active

BKV infection may be identified as early as the first 3 months post transplantation.<sup>5,6</sup> The urological consequences of BKV disease in renal transplant recipients consist primarily of PVAN, and less commonly ureteral stenosis, and ultimately chronic allograft nephropathy and allograft loss.

The diagnosis of BKV disease depends on the presence of BKV as well as evidence of organ dysfunction. There are several methods used to detect BKV infection in renal transplant recipients including urine cytology, PCR, and histopathology. Randhawa et al has recently demonstrated that urine cytology looking for decoy cells is inferior to PCR in screening for BKV infection.<sup>24</sup> Viral particles are shed in the urine, and PCR remains the gold standard for screening of BKV infection with a sensitivity, specificity, positive predictive value, and negative predictive value equal to 100%, 92.1%, 73.6%, and 100%, respectively.<sup>25</sup> However, when BKV viruria is detected, additional confirmatory studies involving histopathological analysis of renal biopsies with light microscopy and immunohistochemistry or electron microscopy are required to confirm the diagnosis of PVAN.<sup>3</sup> In our case series, patients had deteriorating allograft function between 3 and 21 months after transplantation and were screened with urine PCR for BKV, except for A.L. and R.M. because originally there was more of a concern with acute rejection. Upon a positive screen, our patients underwent renal biopsies to confirm histological damage to renal tubular structures caused by BKV and intranuclear inclusions in tubular epithelial cells, as well as the presence of BKV viral particles as visualized by electron microscopy. However, it is challenging to try and distinguish features of rejection versus tubulointerstitial nephritis characteristic of BKV infection as the presence of BKV viruria does not often predict the development of PVAN.<sup>5</sup>

The increasing incidence of PVAN has coincided with the more routine use of triple immunosuppressive maintenance therapy consisting of tacrolimus, MMF and prednisone. Brennan et al in a randomized prospective study observed that 46% and 13% of patients taking tacrolimus-MMF and cyclosporine-MMF developed BK viruria, respectively.<sup>4</sup> By 1 year, 35% of patients developed viruria independent of the type of immunosuppressant used. Although none of their patients developed PVAN, this could be partly explained by ongoing reduction of immunosuppression in response to an elevated BK plasma viral load. In contrast, Bressollette-Bodin et al prospectively showed that tacrolimus increased the incidence of BKV viruria at 6 months after transplantation.<sup>5</sup> At present,

it is not possible to identify whether a specific immunosuppressant or immunosuppressive regimen is responsible for PVAN; however, the impact of newer agents remains to be seen.<sup>26</sup> Nevertheless, it is likely that the overall extent of immunosuppression is the common denominator that increases the risk of developing PVAN as opposed to any particular agent or immunosuppressive regimen.<sup>2</sup> Consistent with this theory, the use of corticosteroids as intravenous boluses in episodes of acute rejection has been found to increase the risk of PVAN.<sup>6</sup> Interestingly, pre-transplant patients with renal disease on corticosteroid therapy had a higher prevalence of BKV infection compared to chronic renal patients not taking corticosteroids suggesting a possibility of viral reactivation by corticosteroid therapy.<sup>27</sup>

The treatment of PVAN remains controversial. The success of reducing immunosuppression has yielded conflicting results, although Brennan et al demonstrated that reducing immunosuppression in response to elevated plasma BK DNA viral load may prevent the development of PVAN.<sup>4</sup> Several strategies to modify immunosuppression have been outlined by Hirsch et al.<sup>13</sup> Our strategy involved first reducing and then tapering off MMF. Tacrolimus was also gradually discontinued in one case (A.T.) and switched to cyclosporine in two other cases (A.L. and R.M.). These strategies had variable results in our series as we had to employ rescue therapies to stabilize allograft function. The allograft functions of A.L. and R.M. appeared to have stabilized after switching tacrolimus to cyclosporine.

Since BKV is a DNA virus, quinolones, which are antibiotics that inhibit DNA-gyrase, have been employed to reduce BKV viral load. Ciprofloxacin has been shown recently to be of success in treating BKV infection in haematopoietic stem cell transplant recipients.<sup>28</sup> In our series, however, ciprofloxacin did not slow down the deterioration of allograft function caused by PVAN. This is perhaps due to the fact that viral load is usually much higher in patients with biopsy-proven PVAN as shown by Hirsch et al,<sup>6</sup> and the activity of ciprofloxacin may not be sufficient to alter the pathogenesis of BKV disease at this stage.

We then employed leflunomide as rescue therapy for patients with deteriorating allograft function and biopsy-proven BKV. Leflunomide is an immunosuppressant with an active metabolite that has antiviral properties. Williams et al have shown that in 15 out of 17 patients with PVAN, leflunomide improved allograft function and progressively reduced the plasma and urine BKV viral load.<sup>29</sup> Similarly, in three cases we were able to rescue and

stabilize allograft function with leflunomide. Currently these patients are being monitored for the potential of developing hepatotoxicity, which is known to be a side effect of leflunomide.

Cidofovir is an antiviral nucleoside analogue of cytosine used in the treatment of CMV retinitis. Kuypers et al have recently demonstrated that 8 out of 21 patients with biopsy-proven PVAN treated with low dose cidofovir resulted in stabilization of allograft function and prolongation of allograft survival with 24 months of follow up.<sup>30</sup> Despite these encouraging results, Farasati et al have suggested that the *in vitro* activity and selectivity of cidofovir was at best modest and that more specific agents need to be developed against BKV.<sup>31</sup> We elected not to use cidofovir given that it is highly nephrotoxic resulting in proteinuria and renal failure in 20% of patients.<sup>32,33</sup>

In addition to PVAN, ureteric stenosis is another complication of BKV infection. Karam et al reported an overall rate of ureteric necrosis of 3.2% (52 out 1629) in renal transplant patients.<sup>8</sup> Twenty five cases of ureteric necrosis were available for histopathological analysis and they identified two cases due to BKV inclusions. Poor blood perfusion of a graft ureter due to damaged adventitia or the presence of a foreign body, such as a ureteric stent, may promote inflammation with reactivation and replication of BKV. The management of ureteric necrosis has been ureteric re-implantation. However, it is unclear what effect rescue therapy will have on BKV-induced ureteric stenosis. In our case of A.B., she has had recurrence of her proximal ureteric stricture currently being managed with long-term stenting. This patient has deferred definitive surgical correction.

Re-transplantation after renal allograft loss due to PVAN has been reported. However, PVAN may recur at a higher rate than in primary transplant recipients.<sup>34-36</sup> Hirsch et al recommended that the absence of BKV replication be confirmed prior to re-transplantation with possible therapeutic approaches that include administration of cidofovir and/or renal transplant nephrectomy with surgical removal of the alloureter.<sup>13</sup>

## Conclusions

The management of urological manifestations of BKV disease is a challenging problem. It has been suggested that PCR testing of urine and/or plasma may be a valuable screening tool. However, definitive diagnosis requires histopathological demonstration of BKV. Although there are no specific antiviral agents against BKV, in our experience reduction of

immunosuppressive therapy and the institution of leflunomide has been beneficial in the stabilization of allograft function. Therefore, early recognition of urological complications and treatment are essential to ensure adequate long-term function of these allografts. □

## References

- Knowles WA, Pipkin P, Andrews N et al. Population-based study of antibody to the human polyomaviruses BKV and JCV and the simian polyomavirus SV40. *J Med Virol* 2003;71:115-123.
- Hirsch HH, Steiger J. Polyomavirus BK. *Lancet Infect Dis* 2003;3:611-623.
- Hirsch HH. BK virus: opportunity makes a pathogen. *Clin Infect Dis* 2005;41:354-360.
- Brennan DC, Agha I, Bohl DL et al. Incidence of BK with tacrolimus versus cyclosporine and impact of preemptive immunosuppression reduction. *Am J Transplant* 2005;5:582-594.
- Bressollette-Bodin C, Coste-Burel M, Hourmant M, Sebillé V, ndre-Garnier E, Imbert-Marcille BM. A Prospective Longitudinal Study of BK Virus Infection in 104 Renal Transplant Recipients. *Am J Transplant* 2005;5:1926-1933.
- Hirsch HH, Knowles W, Dickenmann M et al. Prospective study of polyomavirus type BK replication and nephropathy in renal-transplant recipients. *N Engl J Med* 2002;347:488-496.
- Schmid H, Burg M, Kretzler M, Banas B, Grone HJ, Kliem V. BK virus associated nephropathy in native kidneys of a heart allograft recipient. *Am J Transplant* 2005;5:1562-1568.
- Karam G, Maillet F, Parant S, Souillou JP, Giral-Classe M. Ureteral necrosis after kidney transplantation: risk factors and impact on graft and patient survival. *Transplantation* 2004;78:725-729.
- Erard V, Kim HW, Corey L et al. BK DNA viral load in plasma: evidence for an association with hemorrhagic cystitis in allogeneic hematopoietic cell transplant recipients. *Blood* 2005;106:1130-1132.
- Kausman JY, Somers GR, Francis DM, Jones CL. Association of renal adenocarcinoma and BK virus nephropathy post transplantation. *Pediatr Nephrol* 2004;19:459-462.
- Geetha D, Tong BC, Racusen L, Markowitz JS, Westra WH. Bladder carcinoma in a transplant recipient: evidence to implicate the BK human polyomavirus as a causal transforming agent. *Transplantation* 2002;73:1933-1936.
- Fioriti D, Videtta M, Mischitelli M et al. The human polyomavirus BK: Potential role in cancer. *J Cell Physiol* 2005;204:402-406.
- Hirsch HH, Brennan DC, Drachenberg CB et al. Polyomavirus-associated nephropathy in renal transplantation: interdisciplinary analyses and recommendations. *Transplantation* 2005;79:1277-1286.
- Mengel M, Marwedel M, Radermacher J et al. Incidence of polyomavirus-nephropathy in renal allografts: influence of modern immunosuppressive drugs. *Nephrol Dial Transplant* 2003;18:1190-1196.
- Buehrig CK, Lager DJ, Stegall MD et al. Influence of surveillance renal allograft biopsy on diagnosis and prognosis of polyomavirus-associated nephropathy. *Kidney Int* 2003;64:665-673.
- Awadalla Y, Randhawa P, Ruppert K, Zeevi A, Duquesnoy RJ. HLA mismatching increases the risk of BK virus nephropathy in renal transplant recipients. *Am J Transplant* 2004;4:1691-1696.
- Ramos E, Drachenberg CB, Papadimitriou JC et al. Clinical course of polyoma virus nephropathy in 67 renal transplant patients. *J Am Soc Nephrol* 2002;13:2145-2151.
- Smith JM, McDonald RA, Finn LS, Healey PJ, Davis CL, Limaye AP. Polyomavirus nephropathy in pediatric kidney transplant recipients. *Am J Transplant* 2004;4:2109-2117.
- Toyoda M, Puliyaanda DP, Amet N et al. Co-infection of Polyomavirus-BK and Cytomegalovirus in Renal Transplant Recipients. *Transplantation* 2005;80:198-205.
- Drachenberg C, Hirsch HH, Papadimitriou JC et al. Cost efficiency in the prospective diagnosis and follow-up of polyomavirus allograft nephropathy. *Transplant Proc* 2004;36:3028-3031.
- Kwak EJ, Vilchez RA, Randhawa P, Shapiro R, Butel JS, Kusne S. Pathogenesis and management of polyomavirus infection in transplant recipients. *Clin Infect Dis* 2002;35:1081-1087.
- Drachenberg CB, Papadimitriou JC, Hirsch HH et al. Histological patterns of polyomavirus nephropathy: correlation with graft outcome and viral load. *Am J Transplant* 2004;4:2082-2092.
- Pascual M, Theruvath T, Kawai T, Tolkoff-Rubin N, Cosimi AB. Strategies to improve long-term outcomes after renal transplantation. *N Engl J Med* 2002;346:580-590.
- Randhawa P, Vats A, Shapiro R. Monitoring for polyomavirus BK And JC in urine: comparison of quantitative polymerase chain reaction with urine cytology. *Transplantation* 2005;79:984-986.
- Randhawa PS, Vats A, Zygmunt D et al. Quantitation of viral DNA in renal allograft tissue from patients with BK virus nephropathy. *Transplantation* 2002;74:485-488.
- Halloran PF. Immunosuppressive drugs for kidney transplantation. *N Engl J Med* 2004;351:2715-2729.
- Kaneko T, Moriyama T, Tsubakihara Y, Horio M, Imai E. Prevalence of human polyoma virus (BK virus and JC virus) infection in patients with chronic renal disease. *Clin Exp Nephrol* 2005;9:132-137.
- Leung AY, Chan MT, Yuen KY et al. Ciprofloxacin decreased polyoma BK virus load in patients who underwent allogeneic hematopoietic stem cell transplantation. *Clin Infect Dis* 2005;40:528-537.
- Williams JW, Javaid B, Kadambi PV et al. Leflunomide for polyomavirus type BK nephropathy. *N Engl J Med* 2005;352:1157-1158.
- Kuyper DR, Vandooren AK, Lerut E et al. Adjuvant Low-Dose Cidofovir Therapy for BK Polyomavirus Interstitial Nephritis in Renal Transplant Recipients. *Am J Transplant* 2005;5:1997-2004.
- Farasati NA, Shapiro R, Vats A, Randhawa P. Effect of leflunomide and cidofovir on replication of BK virus in an in vitro culture system. *Transplantation* 2005;79:116-118.
- Vandercam B, Moreau M, Goffin E, Marot JC, Cosyns JP, Jadoul M. Cidofovir-induced end-stage renal failure. *Clin Infect Dis* 1999;29:948-949.
- Bagnis C, Izzidine H, Deray G. Renal tolerance of cidofovir. *Therapie* 1999;54:689-691.
- Ginevri F, Pastorino N, de SR et al. Retransplantation after kidney graft loss due to polyoma BK virus nephropathy: successful outcome without original allograft nephrectomy. *Am J Kidney Dis* 2003;42:821-825.
- Poduval RD, Meehan SM, Woodle ES et al. Successful retransplantation after renal allograft loss to polyoma virus interstitial nephritis. *Transplantation* 2002;73:1166-1169.
- Ramos E, Vincenti F, Lu WX et al. Retransplantation in patients with graft loss caused by polyoma virus nephropathy. *Transplantation* 2004;77:131-133.