

Massive scrotal hematoma following transfemoral cardiac catheterization

Anil A. Thomas, MD,¹ Ryan Hedgepeth, MD,¹ Timur P. Sarac, MD,²
Sandip P. Vasavada, MD¹

¹Glickman Urological and Kidney Institute, Cleveland Clinic Foundation, Cleveland, Ohio, USA

²Department of Vascular Surgery, Cleveland Clinic Foundation, Cleveland, Ohio, USA

THOMAS AA, HEDGEPEETH R, SARAC TP, VASAVADA SP. Massive scrotal hematoma following transfemoral cardiac catheterization. The Canadian Journal of Urology. 2008;15(2):4020-4023.

Scrotal hematoma is a rare and unusual complication of transfemoral cardiac catheterization. We describe the case of a 43-year-old man who presented with a delayed retroperitoneal hemorrhage and massive scrotal hematoma

following cardiac catheterization. Emergent groin exploration was performed with ligation of the inferior epigastric artery and evacuation of the scrotal hematoma. Urological sequelae from transfemoral arterial access are rare. However, scrotal hematoma may occur if bleeding occurs between anatomic fascial planes.

Key Words: scrotal hematoma, inferior epigastric artery, transfemoral, cardiac catheterization

Introduction

More than 500000 coronary interventions are performed annually in the United States.^{1,2} Vascular

complications after cardiac catheterization and percutaneous coronary intervention are common with an overall reported rate of 1.5% to 9%.³⁻⁵ Local vascular complications include hematoma, arterial dissection or occlusion, pseudoaneurysm formation, and arteriovenous fistula. These vascular complications can cause serious morbidity, and up to 40% of patients will require surgical repair.^{5,6}

Groin hematomas and bleeding occur in 5% to 23% of patients after transfemoral access.³ However,

Accepted for publication January 2008

Address correspondence to Dr. Sandip Vasavada, Glickman Urological and Kidney Institute, The Cleveland Clinic Foundation, 9500 Euclid Avenue, A100, Cleveland, Ohio 44195 USA

scrotal hematomas complicating transfemoral cardiac catheterization are rare.⁷⁻⁹ We report a case of massive scrotal hematoma resulting from injury to the inferior epigastric artery following a diagnostic transfemoral cardiac catheterization and review the diagnosis and management.

Case report

A 43-year-old man underwent a diagnostic transfemoral arterial cardiac catheterization for the investigation of atypical chest pain and aortic stenosis. His past medical history was significant for end-stage liver disease secondary to Hepatitis B, hepatocellular carcinoma, and diabetes mellitus type II. Transfemoral arterial access was obtained after the second needle pass by the cardiologist. The diagnostic cardiac catheterization was then performed using a JR4 5-French catheter, and the vascular access was closed using a D-stat Dry® hemostatic bandage (Vascular Solutions, Minneapolis, Minnesota, USA) with manual compression. There were no immediate complications, and the patient was discharged home several hours after the procedure.

Two days later, the patient presented to the Emergency Department with right thigh and scrotal pain. Physical examination revealed inguinal and scrotal swelling and tenderness. His scrotum was grossly enlarged, tense, ecchymotic, and tender on palpation, Figure 1. The patient was found to be in hemorrhagic shock (hematocrit 21%), and he received a transfusion of three units of packed red blood cells. After appropriate resuscitation, a

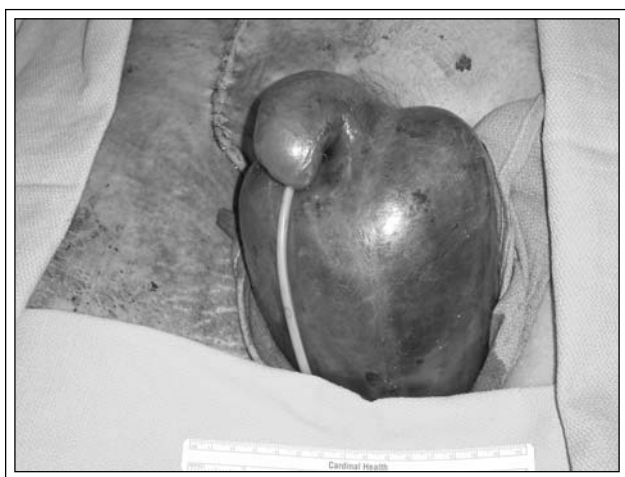


Figure 1. Intraoperative photograph, prior to scrotal exploration, demonstrating massive scrotal hematoma.

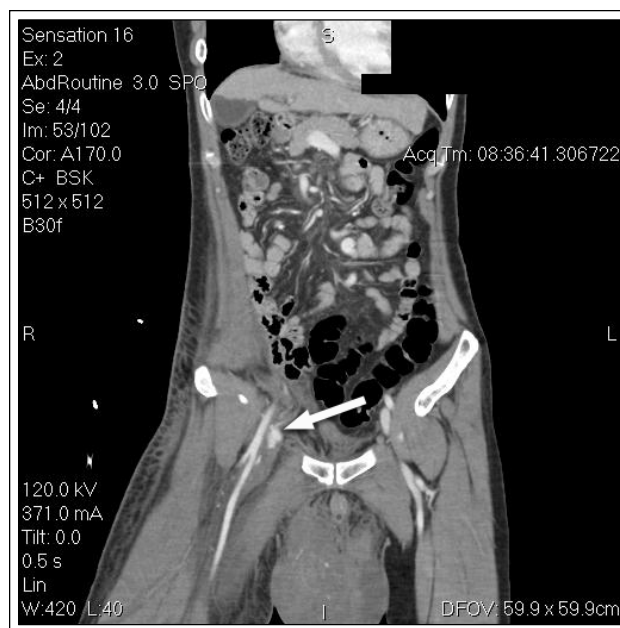

Figure 2. Computed tomography illustrating the right retroperitoneal bleed with a large scrotal hematoma. Extravasation of contrast can be seen from the origin of the inferior epigastric artery from the right femoral artery at the level of the inguinal ligament (arrow).

computed tomography (CT) scan was obtained, and the results revealed a large retroperitoneal hematoma extending into the scrotum with extravasation of the contrast medium from the right inferior epigastric artery, Figure 2. The patient was emergently taken to the operating room for groin exploration. An incision was made at the level of the inguinal ligament and further dissection enabled identification of the common femoral artery and its surrounding branches. After proximal and distal vascular control was obtained, bleeding could be visualized from the right inferior epigastric artery which was then ligated.

A scrotal exploration was then performed through a midline incision of the scrotal raphe. The scrotal hematoma was evacuated, and the scrotum was irrigated. Both testes appeared viable, and no further active bleeding was identified. A Penrose drain was placed through the inferior portion of each hemiscrotum, and the scrotal wound was closed. The scrotal drains were removed 3 days after surgery and the patient otherwise made an uneventful recovery and was discharged home on postoperative day 9. At outpatient follow up 2 weeks later, his inguinal and scrotal wounds were healing well and equal bilateral lower extremity pulses were also noted.

Discussion

Local hematoma formation is a well-recognized vascular complication after femoral arterial or venous catheterizations.¹⁰ Bleeding may spread across fascial planes causing retroperitoneal, intraperitoneal, groin, or abdominal wall hematoma.¹¹ Although infrequent, injury to the inferior epigastric artery can be a potentially fatal complication of cardiac catheterization.¹² The inferior epigastric artery has variable anatomy, but most often it is the last branch of the external iliac artery before crossing the inguinal ligament.¹³ Injury to the inferior epigastric artery can lead to local hematoma formation and discomfort or occult retroperitoneal hemorrhage. Retroperitoneal hemorrhage after cardiac catheterization is a relatively uncommon vascular complication with an overall reported incidence of 0.12% to 1.27%.^{14,15} Bleeding above the inguinal ligament can dissect down the spermatic cord into the scrotum, causing an inguinal mass, groin pain, or scrotal hematoma.¹² Furthermore, significant retroperitoneal blood loss can occur before clinical signs are evident.

Although ultrasound is an excellent imaging tool for scrotal trauma, CT scanning is an expedient and accurate method for identifying the source of bleeding and evidence of retroperitoneal hemorrhage.^{11,16} Other authors advocate the use of femoral angiography in localizing the site of bleeding or to guide treatment based on the patient's clinical symptoms and hemodynamic stability.¹²

In the present case, injury to the inferior epigastric artery during transfemoral arterial cardiac catheterization resulted in a large retroperitoneal bleed and scrotal hematoma. Three previous cases of scrotal hematoma complicating transfemoral catheterization have been reported, two of which were managed conservatively,^{8,9} and another patient required transfusion and surgical drainage.⁷ The present case is unique because the patient developed hemodynamic instability with active bleeding, and the size of the scrotal hematoma warranted prompt surgical exploration and evacuation of the hematoma. A groin incision was initially made by the vascular surgeons to identify and ligate the bleeding inferior epigastric artery. Once hemodynamic control was achieved, a scrotal exploration was then performed by the urological service. Small scrotal hematomas are generally managed conservatively and often resolve on their own. However, large tense scrotal hematomas, as in the present case, can cause significant discomfort and may compromise the viability of the scrotal skin

and testicle, therefore, exploration and evacuation is necessary. In summary, early detection and expeditious management of bleeding sources are critical as these complications have potential for significant morbidity and mortality. □

References

1. Smith SC Jr, Dove JT, Jacobs AK, Kennedy JW, Kereiakes D, Kern MJ, Kuntz RE, Popma JJ, Schaff HV, Williams DO, Gibbons RJ, Alpert JP, Eagle KA, Faxon DP, Fuster V, Gardner TJ, Gregoratos G, Russell RO, Smith SC Jr; American College of Cardiology; American Heart Association Task Force on Practice Guidelines. Committee to Revise the 1993 Guidelines for Percutaneous Transluminal Coronary Angioplasty. ACC/AHA guidelines of percutaneous coronary interventions (revision of the 1993 PTCA guidelines)—executive summary. A report of the American College of Cardiology/American Heart Association Task Force on Practice Guidelines (committee to revise the 1993 guidelines for percutaneous transluminal coronary angioplasty). *J Am Coll Cardiol* 2001;37(8):2215-2239.
2. Douglas JJ, King S III. Development of balloon angioplasty. In: Hurst's the Heart, Manual of Cardiology. 10th ed. New York, NY: McGraw-Hill; 2001:327.
3. Nasser TK, Mohler ER 3rd, Wilensky RL, Hathaway DR. Peripheral vascular complications following coronary interventional procedures. *Clin Cardiol* 1995;18(11):609-614.
4. Applegate RJ, Grabarczyk MA, Little WC, Craven T, Walkup M, Kahl FR, Braden GA, Rankin KM, Kutcher MA. Vascular closure devices in patients treated with anticoagulation and IIb/IIIa receptor inhibitors during percutaneous revascularization. *J Am Coll Cardiol* 2002;40(1):78-83.
5. Waksman R, King SB 3rd, Douglas JS, Shen Y, Ewing H, Mueller L, Ghazzal ZM, Weintraub WS. Predictors of groin complications after balloon and new-device coronary intervention. *Am J Cardiol* 1995;75(14):886-889.
6. Omoigui NA, Califf RM, Pieper K, Keeler G, O'Hanesian MA, Berdan LG, Mark DB, Talley JD, Topol EJ. Peripheral vascular complications in the Coronary Angioplasty Versus Excisional Atherectomy Trial (CAVEAT-I). *J Am Coll Cardiol* 1995;26(4):922-930.
7. Borden TA, Rosen RT, Schwarz GR. Massive scrotal hematoma developing after transfemoral cardiac catheterization. *Am Surg* 1974;40:193-194.
8. Shah J, Middleton S, Derodra J. Massive scrotal haematoma: a complication of percutaneous transluminal angioplasty. *Int J Clin Pract* 2001;55:722.
9. Goessl C, Steffen-Wilke K, Miller K. Leech therapy for massive scrotal hematoma following percutaneous transluminal angioplasty. *J Urol* 1997;158:545.
10. Koreny M, Riedmüller E, Nikfardjam M, Siostrzonek P, Müllner M. Arterial puncture closing devices compared with standard manual compression after cardiac catheterization: systematic review and meta-analysis. *JAMA* 2004;291(3):350-357.
11. Trerotola SO, Kuhlman JE, Fishman EK. CT and anatomic study of postcatheterization hematomas. *Radiographics* 1991;11(2):247-258.
12. Kawamura A, Piemonte TC, Nesto RW, Gossman DE. Retroperitoneal hemorrhage from inferior epigastric artery: value of femoral angiography for detection and management. *Catheter Cardiovasc Interv* 2006;68:267-270.

13. Epstein J, Arora A, Ellis H. Surface anatomy of the inferior epigastric artery in relation to laparoscopic injury. *Clin Anat* 2004;17:400-408.
14. Lubavin BV. Retroperitoneal hematoma as a complication of coronary angiography and stenting. *Am J Emerg Med* 2004;22:236-268.
15. Johnson LW, Esente P, Giambartolomei A, Grant WD, Loin M, Reger MJ, Shaw C, Walford GD. Peripheral vascular complications of coronary angioplasty by the femoral and brachial techniques. *Cathet Cardiovasc Diagn* 1994;31:165-172.
16. Deurdulian C, Mittelstaedt CA, Chong WK, Fielding JR. US of acute scrotal trauma: optimal technique, imaging findings, and management. *Radiographics* 2007;27:357-369.

EDITORIAL COMMENT

The authors describe a complication of massive scrotal hematoma that developed following transfemoral cardiac catheterization. This complication resulted from injury of the inferior epigastric artery during the procedure. The American Heart Association indicates that nearly 600,000 coronary catheterization procedures were performed in 2002.¹ These increased numbers have been sparked by increased effectiveness, improved outcomes and have decreased the need for emergency open cardiac bypass surgeries.

Due to the increasing numbers of interventional procedures involving the groin, we may anticipate that the numbers of resulting urologic complications may increase. We may receive more consultations for patients with groin hematoma, scrotal edema and other vascular complications. Fortunately, most of these complications resolve with best rest, elevation and ice therapy. However, for the patient with arterial injury, treatment is less well defined and often managed on a case-by-case basis. Treatment considerations may include observation, angiography with embolization and open inguinal exploration.

In our institution, one patient had a massive scrotal hematoma following transfemoral cardiac catheterization. He was initially treated conservatively due to stable hemodynamics but later required scrotal and inguinal exploration for clot evacuation. No bleeding vessel was identified. He is well at 6-month follow-up.

This interesting case report provides timely information that will be pertinent to practicing urologists who may be faced with a similar situation in their future practice.

References

1. American Heart Association – Heart Disease Statistics – 2002 Update, Dallas, Texas 2002.

Stanley Zaslau, MD, MBA, FACS
 Program Director
 Associate Professor
 Division of Urology
 West Virginia University
 Morgantown, WV