

---

# Efficacy of the argon beam coagulator alone in obtaining hemostasis after laparoscopic porcine heminephrectomy: a pilot study

Alvaro Lucioni, MD, Marcelo A. Orvieto, MD, Kevin C. Zorn, MD, Tamara Lotan, MD, Edward M. Gong, MD, Gary D. Steinberg, MD, Arie L. Shalhav, MD

Section of Urology, University of Chicago Pritzker School of Medicine, Chicago, Illinois, USA

---

LUCIONI A, ORVIETO MA, ZORN KC, LOTAN T, GONG EM, STEINBERG GD, SHALHAV AL. Efficacy of the argon beam coagulator alone in obtaining hemostasis after laparoscopic porcine heminephrectomy: a pilot study. *The Canadian Journal of Urology*. 2008;15(3):4091-4096.

**Introduction:** The argon beam coagulator (ABC) is used in combination with other hemostatic agents and suture renorrhaphy to obtain hemostasis after laparoscopic partial nephrectomy. We performed a pilot study evaluating the efficacy of the ABC-alone in obtaining hemostasis during laparoscopic heminephrectomy (LHN) in a porcine model.

**Methods:** Eight pigs (4 small (30 kg-40 kg) and 4 large (70 kg-80kg)), underwent bilateral LHN. Hemostasis then was obtained by using the ABC at 120W as a single modality. The collecting system was not repaired. The hilum was unclamped and the renal defect observed for 20 minutes with pneumoperitoneum pressure of 4 mmHg. The animals were survived for 24 hours at which time they

were sacrificed and necropsy performed.

**Results:** All small pigs underwent LHN successfully. Mean pre- and post-op Hgb were 11.2 g/dl and 9.8 g/dl, respectively ( $p = 0.12$ ). In one of the animals, ABC at 150W was required to obtain hemostasis. All but one of the large pigs underwent LHN successfully. One of the animals had continuous bleeding despite ABC after right LHN and a completion nephrectomy was performed. Pre and postoperative Hgb for the large pigs were 9.9 g/dl and 9.3 g/dl, respectively ( $p = 0.24$ ).

**Conclusions:** The ABC-alone was successful in obtaining hemostasis in all but two of the renal units in both small and large pigs. The two hemostatic failures were noticeable immediately after hilar unclamping. Our data suggest that ABC-alone provides adequate hemostasis when applied to small-caliber vessels. Further long term studies are needed to fully evaluate the efficacy of the ABC.

**Key Words:** laparoscopic partial nephrectomy, argon beam coagulator, hemostasis

---

## Introduction

Laparoscopic partial nephrectomy (LPN) has been proven an effective treatment option for patients with T1a renal tumors.<sup>1-4</sup> In the last decade, as urologists have become more comfortable with laparoscopic

techniques, the number of LPN performed has increased significantly.<sup>1</sup> Patients undergoing LPN have a more rapid recovery as compared with open partial nephrectomy (OPN), although LPN is associated with higher postoperative complication rates.<sup>3,4</sup> One of the most technically challenging aspects of the procedure is the resection of the tumor with appropriate margins and repair of the renal defect to obtain adequate hemostasis and closure of the collecting system. This step of the procedure demands good intracorporeal suturing skills in order to close the renal defect in a timely fashion. Several techniques to obtain hemostasis have been described,

---

Accepted for publication February 2008

Address correspondence to Dr. Alvaro Lucioni, Department of Surgery, Section of Urology, University of Chicago Pritzker School of Medicine, 5841 S. Maryland Avenue, MC 6038, Chicago, Illinois 60637 USA

including intracorporeal suturing, application of various tissue sealants (fibrin sealants, hydrogels, collagen based adhesives), and vascular coagulation with the argon beam coagulator, bipolar cautery, or laser.<sup>5-10</sup> Unfortunately, there is no consensus as to which of these techniques is most effective.

The argon beam coagulator (ABC) is a non-contact electrocautery device. It uses alternating current delivered to the tissue through ionized argon gas. The electric current travels through the gas in arcs that allow for uniform distribution of energy across the tissue. Traditional electrocautery devices emit electric current unevenly and over a large area which leads to more necrotic tissue and poor healing.<sup>11</sup> Apart from less tissue damage, the ABC allows for better hemostasis by blowing blood and fluid away from the target site, causing less smoke plume, preventing carbonization of the tissue, and allowing the formation of a homogenous eschar.<sup>11</sup> The ABC has been widely used in a variety of surgical fields and has been proven to be an effective and safe method for hemostasis.<sup>12-15</sup>

In nephron-sparing surgery, the ABC has been used in conjunction with other hemostatic devices, such as intracorporeal suturing of vessels and tissue sealants. There is no study that has evaluated the use of ABC-alone as a hemostatic technique. We have performed a pilot study to evaluate the efficacy of the ABC-alone in obtaining hemostasis after laparoscopic heminephrectomy (LHN) in a porcine model.

## Materials and methods

The study was performed with the approval of our Institutional Animal Care and Use Committee on eight non-pregnant female pigs. These included four small animals weighing 30 kg-40 kg and four large animals, weighing 70 kg-80 kg. All animals underwent right followed by immediate left LHN.

### *Laparoscopic heminephrectomy (LHN)*

The pigs were placed in the respective modified lateral decubitus position and pneumoperitoneum was then obtained via Veress needle access. A total of three or four laparoscopic ports were inserted. The renal hilum was exposed and renal artery and vein fully dissected. The kidney was then released from its attachments to the retroperitoneum. The renal artery and vein were then clamped using a laparoscopic bulldog clamps (Aesculap, Center Valley, PA). The heminephrectomy was performed 2 cm below the renal hilum using sharp dissection with scissors. The renal defect was then completely coagulated systematically from anterior to posterior using the laparoscopic ABC

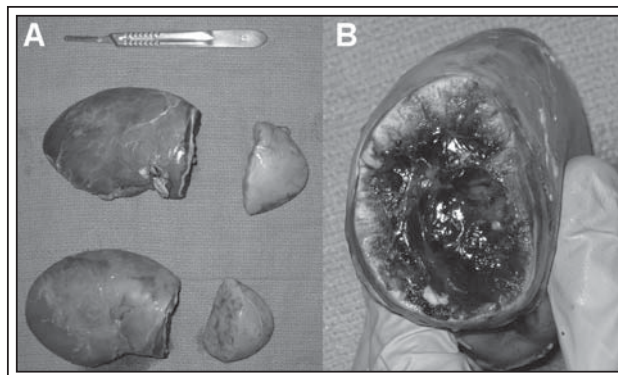
at 120W setting (ConMed Electrosurgery, Billerica, MA). Repeat application was used as needed to any areas that were still bleeding. No attempt was made to close the collecting system. The lower pole specimens were left inside the abdominal cavity and removed when the animal was euthanized. After Bulldog unclamping, the kidney was observed for 20 minutes under low intraabdominal pressures (4 mmHg). Any bleeding from the renal defect was suctioned and collected to measure blood loss. If significant bleeding occurred (defined by a blood volume of greater than 6.5 ml/kg suctioned out of the abdomen) then the renal artery and vein were clamped and completion nephrectomy performed. If significant bleeding was noted after performing the right heminephrectomy, then a completion nephrectomy was performed prior to proceeding to the contralateral heminephrectomy. If there was significant bleeding after the second heminephrectomy then the animal was euthanized. The animals were survived for 24 hours only if at least one of the kidneys remained viable and non-significant bleeding was noted during the 20 minute observation period. The animal was euthanized 24 hours following surgery underwent necropsy.

### *Perioperative evaluation*

Hemoglobin (Hgb) level was assessed preoperatively as well as 1 hour following the procedure.

### *Pathological and histological analysis*

After euthanasia, the abdomen was open and the retroperitoneum exposed. The renal artery and vein were ligated and the kidneys, with their respective lower pole, were removed for analysis, Figure 1. The remaining kidney weight was compared to the



**Figure 1.** Renal units after necropsy. A. Picture showing the kidneys with their respective lower pole after LHN. B. Coagulated surface of the kidney 24 hours after hemostasis with the ABC.

weight of the previously removed kidney pieces to determine the percent of the kidney that was removed. The remaining coagulated kidney was saved for pathological and histological examination. The abdominal cavity was also be explored to evaluate for hematomas, urinomas, and other possible postoperative findings. Sample sections of each kidney were cut and fixed to examine the coagulated surface. The cut edge of the lower pole was also fixed for analysis. Kidney pieces were fixed in 10% neutral buffered formalin and then sectioned and submitted for standard processing and paraffin embedding. Five micrometer tissue sections were stained with hematoxylin and eosin. Images were captured on an Olympus BX41 light microscope (Melville, NY) with a Zeiss Axiocam digital camera (Oberkochen, Germany). The diameter of the largest vessels that were closest to the coagulated area were measured.

#### Statistical analysis

Quantitative data are expressed as mean ( $\pm$  SEM). Statistical analysis was performed using Student's t test. A p-value  $< 0.05$  was considered statistically significant.

## Results

#### Surgical outcomes (Table 1)

All small animals underwent bilateral LHN without significant bleeding requiring completion nephrectomies. The average warm ischemia time was 6 minutes (range 5-10 minutes). The average time of ABC use was 45 seconds (30-50 seconds). The mean blood loss (BL) was 117.5 ml (range 60 ml-250 ml). The average postoperative Hgb decreased from 11.25 g/dl to 9.8 g/dl, however this drop was not statistically significant ( $p = 0.16$ ). Of note, one of the animals (pig # 4) had the left LHN done only 1 cm from the hilum. After unclamping the hilum, a large bleeding vessel was identified which led to a BL of 250 ml. Hemostasis was only achieved after increasing the ABC power to 150W without the need of clamping the hilum. None of the animals had evidence of hemorrhage prior to euthanasia 24 hours after surgery. Necropsy only revealed small urinomas (10 ml-20 ml) in all animals except pig #4 who also was noted to have a small left hematoma (20 ml) by the kidney.

With regards to the large animals, all but one of the pigs underwent successful bilateral LHN.

TABLE 1. Summary of surgical outcomes after LHN using the ABC-alone for hemostasis

| Animal         | Weight<br>kg | EBL<br>ml    | Preop<br>Hgb | Postop<br>Hgb | Nephrectomy | % right<br>LHN | % left<br>LHN | Necropsy<br>findings                       |
|----------------|--------------|--------------|--------------|---------------|-------------|----------------|---------------|--|
| <b>Small</b>   |              |              |              |               |             |                |               |  |
| Pig #1         | 34.7         | 60           | 10.6         | 9.3           | No          | 17.8           | 16.8          | 10 ml urinoma,<br>no hematoma              |
| Pig #2         | 33.8         | 100          | 11.8         | 11.4          | No          | 29.7           | 26.2          | 15 ml urinoma,<br>no hematoma              |
| Pig #3         | 38           | 60           | 12.5         | 9.1           | No          | 19.1           | 21.4          | 10 ml urinoma,<br>no hematoma              |
| Pig #4         | 38.4         | 250          | 10.1         | 9.4           | No          | 34.1           | 29.0          | 20 ml urinoma,<br>20 ml left hematoma      |
| <b>Average</b> | <b>36.2</b>  | <b>117.5</b> | <b>11.3</b>  | <b>9.8</b>    |             | <b>25.2</b>    | <b>23.4</b>   |  |
| <b>Large</b>   |              |              |              |               |             |                |               |  |
| Pig #5         | 73.2         | 100          | 10.6         | 10.6          | No          | 18.8           | 22.0          | 15 ml urinoma,<br>no hematoma              |
| Pig #6         | 77.8         | 100          | 9.9          | 8.1           | No          | 15.0           | 27.7          | 10 ml urinoma,<br>no hematoma              |
| Pig #7         | 69.4         | 250          | 9.1          | 9.1           | Yes, right  | 15.4           | 18.0          | 15 ml urinoma,<br>40 ml right hematoma     |
| Pig #8         | 74.6         | 100          | 10           | 9.3           | No          | 34.1           | 17.8          | 20 ml urinoma,<br>15 ml bilateral hematoma |
| <b>Average</b> | <b>73.8</b>  | <b>137.5</b> | <b>9.9</b>   | <b>9.3</b>    |             | <b>20.8</b>    | <b>21.4</b>   |  |

The average warm ischemia time was 7 minutes (range 5-10 minutes). The average time of ABC use was 50 seconds (35-70 seconds). The mean BL among this group was 137.5 ml (range 100 ml-250 ml). The mean postoperative Hgb did not decreased significantly (9.9 g/dl versus 9.3 g/dl,  $p = 0.28$ ). Pig # 7 underwent a completion right nephrectomy after LHN due to persistent bleeding despite use of the ABC at 150W. The EBL for this case was 250 ml. Necropsy revealed a moderate size (40 ml) hematoma in this animal. None of the animals had evidence of significant bleeding prior to euthanasia. Small urinomas (10 ml-20 ml) were found in all animals during necropsy.

### Histological findings

*Effect of ABC on renal tissue:* Histological analysis of the coagulated surface of the kidneys demonstrated a three layer effect of the ABC, Figure 2. The first or superficial layer showed evidence of coagulative necrosis. The second layer consisted of viable tissue that seems to have been "spared" with normal appearing glomeruli and tubules. Deeper to this layer there was an area demonstrating tubular and glomerular ischemia. Within this layer, multiple large thrombosed vessels were noted. The remainder of the kidney appeared unchanged. The average depth of penetration (DP) of the ABC was 0.64 mm (range: 0.1 mm-1.5 mm) in all animals. The average DP in the small animals was

0.85 mm (range 0.3 mm -1.5 mm) compared to 0.46 mm (range 0.1 mm-0.9 mm) in the larger animals ( $p = 0.06$ ). Of note, the depth of penetration on the small animal requiring the ABC at 150W was 1.5 mm.

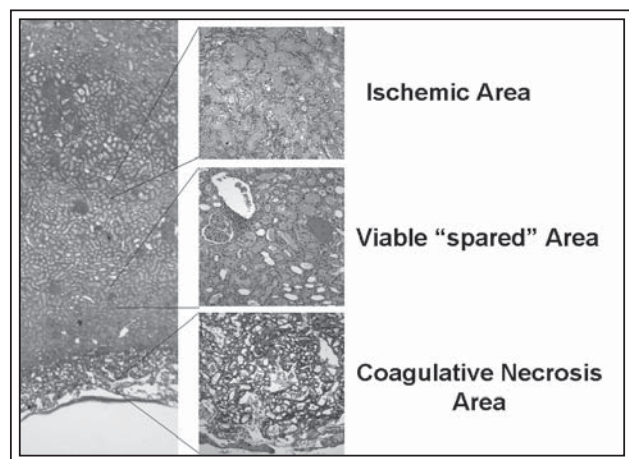
*Vessel size:* Given the extensive necrosis at the coagulated edge of the kidney the caliber of the vessels was measured on the cut edge of the lower poles. Histologic analysis revealed vessels ranging between 0.2 mm-0.4 mm and 0.5 mm-1.0 mm in diameter for the small and large pigs, respectively.

Histological analysis of the coagulated surface of the kidneys demonstrated a three layer effect of the ABC, Figure 2. The first or superficial layer showed evidence of coagulative necrosis. The second layer consisted of viable tissue that seems to have been "spared" with normal appearing glomeruli and tubules. Deeper to this layer there was an area demonstrating tubular and glomerular ischemia.

### Discussion

There are various methods to obtain tissue hemostasis after LPN, including the use of the ABC in conjunction with tissue sealants and suture renorrhaphy. During LPN, one of the goals of the surgeon is to limit the warm ischemia time. More rapid methods of hemostasis may aid the surgeon in achieving this goal. In LPN, where the mass removed is small and exophytic, and the collecting was not violated, using the ABC alone may be effective in obtaining hemostasis. We performed LHN in pigs to create large tissue defects and see if the ABC alone was efficacious in obtaining hemostasis. If the ABC is effective after LHN then it may also be effective during LPN with smaller tissue defects.

Our pilot study demonstrates that the ABC-alone is a feasible and effective method to obtain hemostasis in a large animal model after LHN. The warm ischemia time was only 6 and 7 minutes in the small and large animal groups, respectively. Only one of 16 renal units, in the larger animal model, required completion nephrectomy due to continuous bleeding after ABC use. One renal unit in the small animal group required a higher power setting on the ABC to coagulate a bleeding vessel. This likely occurred due to an incision 1 cm from the hilum where vessel size was greater. The two hemostatic failures were immediately noticeable after unclamping the hilum. All other units did not show evidence of significant intraoperative bleeding or postoperative bleeding after 24-hour survival. Histological analysis showed that the ABC was able to prevent bleeding from vessels up to 1.0 mm in size without causing major tissue damage. The average DP of the ABC was only 0.64 mm. However, all renal units



**Figure 2.** Histological analysis of the coagulated surface of the kidneys demonstrating a three layer effect of the ABC (12.5x and 50x). The first or superficial layer shows evidence of coagulative necrosis. The second layer consists of viable tissue that seems to have been "spared" with normal appearing glomeruli and tubules. Deeper to this layer there is an area demonstrating tubular and glomerular ischemia.



had evidence of urinomas postoperatively, suggesting that the ABC was not effective in closing the collecting system.

Histological analysis of the coagulated surface of the kidneys demonstrated a three layer effect of the ABC. The first or superficial layer showed evidence of coagulative necrosis. The second layer consisted of viable tissue that seems to have been "spared" with normal appearing glomeruli and tubules. Deeper to this layer there was an area demonstrating tubular and glomerular ischemia. As described in previous studies, it is likely that the coagulative necrosis found in the first or superficial layer was the direct effect of the ABC on the tissue.<sup>16</sup> The ischemic changes encountered in the third or deeper layer may likely be secondary to the warm ischemia and not a direct effect of the ABC alone. The average depth of tissue penetration by the ABC was 0.64 mm. This is less than described in previous studies. Hernandez et al using the ABC at 130W described an average tissue penetration of 2.4 mm, of which 0.87 mm was a coagulative necrosis layer and 1.09 mm was a carbonization layer. Of note, in this study the authors did close the tissue defect with suture. In our study we used a lower power setting (120W) and did not close the tissue defect. This may have allowed for sloughing of the carbonization layer, which was not observed in our histological analysis.

Our findings are consistent with those found when using the ABC in open partial nephrectomies.<sup>16</sup> Using a canine model, Hernandez et al demonstrated that ABC-alone was superior to the traditional hemostatic methods with suturing with regards to EBL and surgical time. In their study, the 32 partial nephrectomies (four per animal) were performed and either suture ligation or the ABC (130W) was used for coagulation. All animals were survived for 24 hours except for two animals that were survived for 48 hours and 20 days. Mean EBL was 135 cc in the ABC group compared to the 276 cc in the suture ligation group. Further, studies have also demonstrated that the ABC is also effective during resection of other parenchymal organs such as the spleen and liver.<sup>17</sup> The ABC-alone is extensively used in the field of gynecology for hemostasis after uterine surgery, complicated deliveries, and endometriosis.<sup>12,18</sup> Hepatobiliary surgeons have also used the ABC effectively during liver resections.<sup>15,19</sup>

In OPN and LPN, the ABC has been also effectively used as an adjunct to other hemostatic devices. During LPN, various surgeons will use the ABC together with tissue sealants and suturing of the renal parenchyma for hemostasis. There are reports however that care must be taken during the use of ABC while also suturing

given that the ABC may compromise the integrity of the suture material.<sup>20</sup> Despite its effectiveness during liver, spleen and open renal surgery, there are no clinical studies demonstrating the use of ABC-alone for hemostasis after LPN. The potential advantages of using the ABC-alone for hemostasis when compared to suture renorrhaphy include decrease warm ischemia time and the ability to allow for better hemostasis and tissue visualization by blowing blood and fluid away from the target site. When compared to standard electrocautery, the ABC causes less smoke plume, prevents carbonization of the tissue, and allows for the formation of a homogenous eschar.<sup>11,16</sup> Despite its effectiveness there is concern for the use of ABC because of its effect on the rest of the renal parenchyma, risk of argon gas embolus, and inability to close the collecting system.<sup>16,21</sup> With regards to the effect of ABC on the renal parenchyma, Hernandez et al have demonstrated that the depth of tissue injury by the ABC ranges between 2 mm-4 mm in both acute and long term evaluation.<sup>16</sup> Though the risk of argon gas embolus is real, if the renal hilum is clamped during LPN there should be minimal risk. Finally, the ABC has not been shown to aid in the closure of the collecting system in our study and others.<sup>16</sup> Thus, if the collecting system is entered, suturing of the parenchyma or use of other sealant should be performed to avoid long term complications of urine leak.

It is important to emphasize that our investigation is a pilot study to evaluate at feasibility of using the ABC-alone for hemostasis after LHN. As such, there are some limitations to our study that are worth mentioning. First, we only evaluated the short term effectiveness of the ABC-alone for hemostasis. The animals were only survived for 24 hours after surgery. Studies have demonstrated that after nephron-sparing surgery there is risk for both acute, as well as delayed bleeding.<sup>22,23</sup> Another delayed risk is the formation of a vascular or urinary fistula, as well as pseudoaneurysms. We cannot deduce any conclusion with regards to the ability of the ABC-alone to reduce the risk of delayed bleeding or fistula formation or other long term complications. Further investigations are being performed to evaluate the risk of delayed bleeding or fistula formation after LHN using the ABC-alone by our group. Second, during LHN the collecting system is opened and not repaired and thus all animals experienced a urine leak. Further, it is also possible that use of the ABC-alone for hemostasis may affect the ability to close the collecting system adequately.<sup>20</sup> Our pilot study suggests that the ABC alone is effective for acute hemostasis but if the collecting system is entered it must be repaired by other methods such as

## Efficacy of the argon beam coagulator alone in obtaining hemostasis after laparoscopic porcine heminephrectomy: a pilot study

suturing. Further, any large bleeding vessels may have to be closed by means other than the ABC. As such, laparoscopic surgeons must be comfortable with other techniques to obtain hemostasis and collecting system closure such as intracorporeal suturing. Third, there was one animal that required the use of ABC at a power of 150W. Histological analysis did not show evidence of further tissue damage in this animal compared to those where the ABC was used at 120W. No long term effect of the use of 150W power was evaluated by this study. Finally, one must be cautious when interpreting results from an animal model and apply our findings in clinical setting. Further long term studies in animal models as well as in patients are necessary to be certain of the efficacy of the ABC alone for hemostasis.

Despite these limitations, our pilot study does demonstrate the feasibility and short term efficacy of the ABC-alone for hemostasis after LHN. Only one of the 16 units required completion nephrectomy after the ABC failed to obtain adequate hemostasis. Further study is needed to evaluate the risk of delayed bleeding and other complications after using the ABC-alone for hemostasis after LPN. □

### References

1. Beasley KA, Omar MA, Shaikh A, Bochinski D et al. Laparoscopic versus open partial nephrectomy. *Urology* 2004;64(3):458.
2. Link RE, Bhayani SB, Allaf ME, Varkarakis I et al. Exploring the learning curve, pathological outcomes and perioperative morbidity of laparoscopic partial nephrectomy performed for renal mass. *J Urol* 2005;173:1690.
3. Gill IS, Matin SF, Desai MM et al. Comparative analysis of laparoscopic vs. open partial nephrectomy for renal tumors in 200 patients. *J Urol* 2003;170:64.
4. Desai MM, Gill IS. Laparoscopic partial nephrectomy for tumor: current status at the Cleveland Clinic. *BJU Int* 2005;5(2):41.
5. Desai MM, Gill IS, Kaouk JH, Matin SF, Novick AC. Laparoscopic partial nephrectomy with suture repair of the pelviciceal system. *Urology* 2003;61:99.
6. Wilhelm DM, Organ K, Saboorian MH, Napper C, Pearle MS, Cadeddu JA. Feasibility of laparoscopic partial nephrectomy using pledgeted compression sutures for hemostasis. *J Endourol* 2003;17:223.
7. Organ K, Wilhelm D, Lindberg G, Lotan Y, Napper C, Hoopman J, Pearle MS, Cadeddu JA. Laparoscopic partial nephrectomy with diode laser: porcine results. *J Endourol* 2002;16:749.
8. Barret E, Guillonnet B, Cathlineau X, Validire P, Vallancien G. Laparoscopic partial nephrectomy in the pig: Comparison of three hemostasis techniques. *J Endourol* 2001;15:307.
9. Bernie JE, NG J, Bargman V, Gardner T, Cheng L, Sundaram CP. Evaluation of hydrogel tissue sealant in porcine laparoscopic partial-nephrectomy model. *J Endourol* 2005;19:1122.
10. Finley DS, Lee DI, Eichel L, Uribe CA, McDougall EM, Clayman RV. Fibrin glue-oxidized cellulose sandwich for laparoscopic wedge resection of small renal lesions. *J Urol* 2005;173:1477.
11. Scarantino SE, Reilly JG, Moretti ML, Pillari VT. Argon beam coagulation in the management of placenta accreta. *Obstet Gynecol* 1999;94:825.
12. Kulakov VI, Adamian LV, Kiselev SI, Yarotskaya EL, Gobulev G. Argon Beam Coagulator in Laparoscopic Gynecologic Surgery. *J Am Assoc Gynecol Laparosc* 1996;3(Suppl 4):S23.
13. Sutton C. Power sources in endoscopic surgery. *Curr Opin Obstet Gynecol* 1995;7(4):248.
14. Kletscher BA, Lauvret RW, Segura JW. Nephron-sparing laparoscopic surgery: techniques to control the renal pedicle and manage parenchymal bleeding. *J Endourol* 1995;9(1):23.
15. Croce E, Azzola M, Russo R, Golia M, Angelini S, Olmi S. Laparoscopic liver tumour resection with the argon beam. *Endosc Surg Allied Technol* 1994;2(3-4):186.
16. Hernandez AD, Smith Jr JA, Jeppson KG, Terreros DA. A controlled study of the argon beam coagulator for partial nephrectomy. *J Urol* 1990;143:1062.
17. Van Way CW, Ketch L, Stieglmann A, Lance W. A comparison of ionized noble gas electrocoagulation with spray-mode electrocoagulation in canine liver and spleen. Scientific Poster, 72<sup>nd</sup> Annual Clinical Congress, ACS, 1986.
18. Daniell JF, McTavish G, Kurtz BR, Tallab F. Laparoscopic Use of Argon Beam Coagulator in the Management of Endometriosis. *J Am Assoc Gynecol Laparosc* 1994;1(4, Part 2):S9.
19. Kaneko H, Takagi S, Shiba T. Laparoscopic partial hepatectomy and left lateral segmentectomy: technique and results of a clinical series. *Surgery* 1996;120(3):468.
20. Conradie MC, Landman J, Monga M, Rehman J, Clayman RV. Effect of Argon-Beam Coagulation on the Integrity of Suture Material. *J Endourol* 2003;16(3):191.
21. Fatal gas embolism caused by overpressurization during laparoscopic use of argon enhanced coagulation. *Health Devices* 1994;23(6):257.
22. Hamm FC, Finkelstein P. Partial nephrectomy. *J Urol* 1959;82:625.
23. Goldstein AE, Abeshouse BS. Partial resections of the kidney. *J Urol* 1937;38:15.