

# Gastrointestinal stromal tumors presenting as a prostatic mass

Gustavo de la Roza, MD,<sup>1</sup> Asghar Naqvi, MD,<sup>1</sup> Kimball Clark, MD<sup>2</sup>

<sup>1</sup>Department of Pathology, SUNY-Upstate Medical University, Syracuse, New York, USA

<sup>2</sup>Department of Radiology, SUNY-Upstate Medical University, Syracuse, New York, USA

---

DELA ROZA G, NAQVI A, CLARK K. Gastrointestinal stromal tumors presenting as a prostatic mass. The Canadian Journal of Urology. 2009;16(1):4502-4506.

*Gastrointestinal stromal tumors (GISTs) are a rare and heterogeneous group of spindle cell neoplasms that have also been reported outside of gastrointestinal (GI) tract. These tumors are characterized by somatic mutations of c-KIT (CD117), a proto-oncogene that encodes a receptor tyrosine kinase normally expressed in the interstitial cell of Cajal that control the GI smooth muscle peristalsis, and an exquisite sensitivity to the action of the tyrosine kinase inhibitor imatinib mesylate (STI571; Gleevec). We report two cases of gastrointestinal stromal tumor identified on prostatic biopsies, where a primary prostatic sarcoma was considered in the differential diagnosis. In one of the cases, there was extensive local disease involving prostate, rectum,*

*and pelvic wall, as well as metastatic disease that quickly lead to the patient's death despite aggressive treatment with imatinib mesylate and conventional chemotherapy. In the other case, the tumor was mostly confined to the rectum but also focally extended into the prostate capsule. The patient underwent resection and was alive without disease 18 months after surgery. In both cases, tissue samples from prostate and the rectum showed a malignant spindle cell neoplasm, which was positive for CD117 (c-kit). Given their unique clinical management, gastrointestinal stromal tumors should be considered in the differential diagnosis of spindle cell lesions on prostatic needle biopsies and CD117 should be added to the immunohistochemical panel in the work-up of such lesions to avoid misinterpreting them as primary prostatic neoplasms.*

**Key Words:** GIST, prostate, rectum

---

## Introduction

Gastrointestinal stromal tumors (GISTs) are a rare and heterogeneous group of neoplasms. For a long time their origin and nomenclature was a subject of much controversy. In 1983, Mazur and Clark introduced the more generic designation "stromal tumor" for these lesions.<sup>1</sup> The putative cell of origin of GIST is the interstitial cell of Cajal (ICC),<sup>2</sup> which is the pacemaker cell of the gastrointestinal (GI) muscles. It is known that ICC expresses the gene product of c-kit, a proto-oncogene that encodes a receptor tyrosine kinase, Kit. The morphologic features of GIST are variable and

their biologic behavior is difficult to predict. GISTs occur in the entire gastrointestinal (GI) tract, but have also been described in the omentum, mesentery, and retroperitoneum without evidence of a GI primary neoplasm.<sup>3</sup> A few case reports in the literature discuss the presence of primary GIST in the prostate, gallbladder, liver and in a few other sites.<sup>4,5</sup> We discuss the clinical, radiological, and pathological findings in two patients with GIST, who were initially thought to have a primary tumor of the prostate.

## Clinical findings

### Case 1

A 48-year-old man presented with difficulty in micturition and bloody stools. Physical examination revealed a large, non-tender, nodular mass of prostate upon digital rectal examination. Serum prostatic specific antigen (PSA) was not tested. A computed

---

Accepted for publication September 2008

Address correspondence to Dr. Gustavo de la Roza, SUNY-Upstate Medical University, Department of Pathology, WSK 2106, 750 East Adams Street, Syracuse, New York 13210 USA

tomographic (CT) scan revealed a large mass completely filling the pelvis. Metastatic work-up was negative. Transrectal prostatic needle biopsies were performed and the diagnosis of GIST was based on morphological and immunohistochemical findings. The patient underwent a pelvic exenteration, which comprised a resection of the rectum, urinary bladder, and prostate. On follow-up, the patient was doing well 18 months after surgery without evidence of disease.

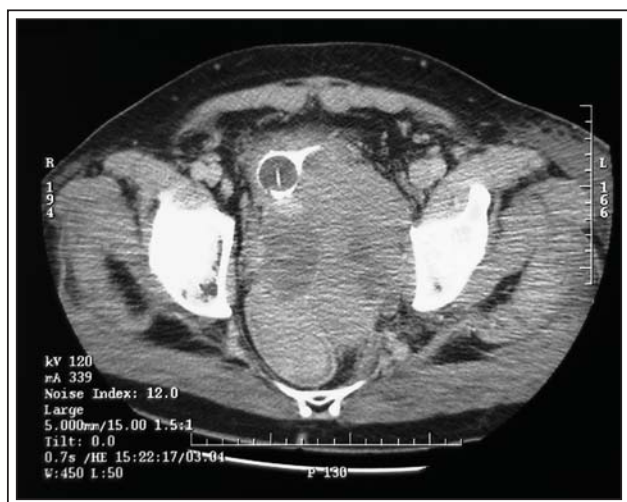### Case 2

A 46-year-old man presented with bloody bowel movements. A 6 cm polypoid rectal mass was found on colonoscopy at 3 cm from the anal verge and a forceps endoscopic biopsy of the mass was taken and a GIST tumor was diagnosed. A CT scan of the pelvis revealed a large pelvic mass between the rectum and the bladder, extending into the pelvic sidewall, Figure 1. A chest CT scan showed multiple pulmonary nodules consistent with metastatic disease. A subsequent bowel obstruction led to a laparoscopic loop colostomy. Serum PSA was within normal limits (0.2 ng/ml). The patient also underwent a cystoscopy during which a prostatic wedge biopsy was performed. The biopsy findings were similar to those of the rectal biopsy and consistent with GIST. The patient initially received imatinib mesylate (Gleevec), which was discontinued after 3 months because of the lack of clinical improvement and continuous progression of the disease. He then received three cycles of MAID (Doxorubicin, Dacarbazine, Ifosfamide, Mesna) chemotherapy, despite which the

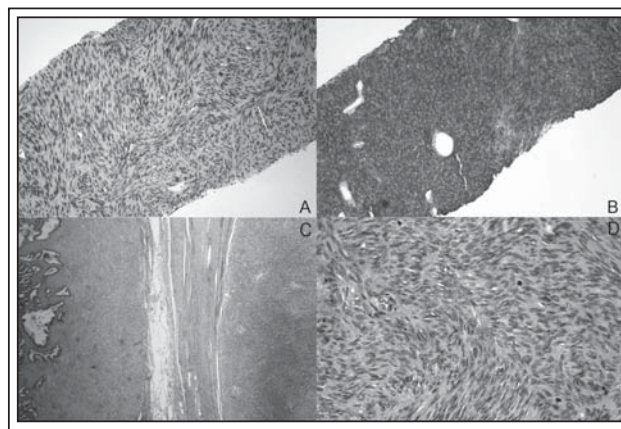
patient developed bladder outlet obstruction and brain metastases. A follow-up CT scans of the thorax and abdomen revealed an increase in the size of the intrapelvic mass, bilateral hydronephrosis, a 3.2 cm right hepatic lesion, and multiple additional subpleural lung nodules. Radiation therapy and corticosteroids were added, but the patient died as a result of sepsis.

### Pathologic findings

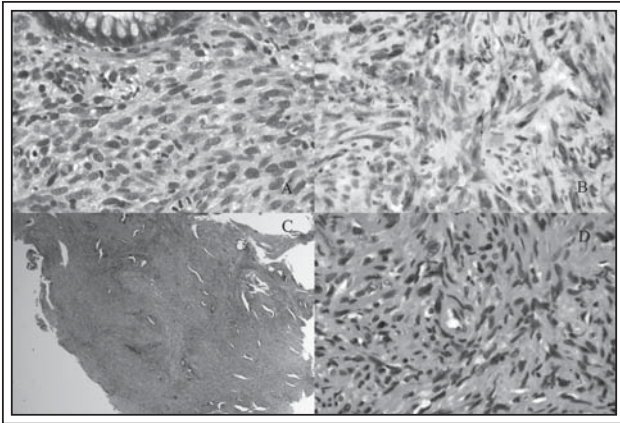
All pathological samples were fixed in 10% buffered formalin, embedded in paraffin, and stained with hematoxylin and eosin. The histological features of the tumor present in the prostatic needle biopsy in Case 1, as well as the rectal and prostatic wedge biopsies in Case 2, were very similar. The tumor in all samples consisted of a cellular proliferation of spindle cells with centrally located, oval, hyperchromatic nuclei with inconspicuous nucleoli, and variably abundant pale staining cytoplasm without distinct cytoplasmic borders. In Case 1, the tumor showed marked increased cellularity, a storiform pattern, abundant mitotic figures and only mild cytologic atypia. The tumor cells were arranged in well formed fascicles with focal areas of nuclear palisading, Figure 2a. In comparison, the tumor in Case 2 was not



**Figure 1.** Case 2 CT scan of the pelvis. A 9 cm heterogenous mass fills the pelvis, displaces and compresses the bladder anteriorly and to the right and displaces the rectum posteriorly and to the right.



**Figure 2.** Case 1 Histology. a) High power view of H&E stain from the prostatic needle biopsy showing marked increased cellularity and a storiform pattern; b) High power view of CD117 (c-kit) immunohistochemical stain showing strong and diffuse cytoplasmic staining of tumor cells in prostatic needle biopsy; c) Scanning view of H&E stain from exenteration specimen showing the interface between the rectal tumor and the seminal vesicle; d) High power view of H&E stain of rectal tumor showing active mitotic activity and identical morphology to prostatic needle biopsy.



**Figure 3.** Histology Case 2. a) High power view of H&E stain from tumor in rectal biopsy. Note benign rectal gland in upper left corner; b) High power view of CD117 (c-kit) immunohistochemical stains of tumor cells in rectal biopsy; c) Scanning view of H&E stain from the prostate biopsy showing spindle tumor cells diffusely infiltrating around benign glands; d) High power view of H&E stain from the prostate biopsy showing moderate atypia and collagenous stroma.

as cellular, the fascicular pattern was less pronounced, but there was more cytologic atypia and more collagen deposition, Figure 3d. The tumor permeated the stroma around the colonic and prostatic glands, Figures 3a and 3c. Necrosis was focally seen in all samples.

The pelvic exenteration specimen in Case 1 consisted of a fused portion of rectum, prostate and bladder. There was a well defined, lobulated, tan-white to gray, and focally necrotic mass measuring 13.0 cm x 8.0 cm x 7.5 cm between the posterior wall of the prostate and the anterior wall of the rectum. The rectal mucosa was intact and both the bladder and prostate were free of tumor. The morphological features of the tumor were identical to those of the initial prostatic needle biopsy, Figure 2d. There was full thickness invasion of the rectal wall with extension to the capsules of the prostate and seminal vesicles, Figure 2c. The tumor, however, did not invade the prostatic or seminal vesicle parenchyma, bladder wall, or the rectal mucosa. There were large areas of necrosis and a high mitotic rate (10 per 50 high power fields).

Immunohistochemical studies of paraffin embedded tissue from the prostatic needle biopsy of Case 1 and the rectal biopsy of Case 2 were performed. The studies were done on a Biotek Solutions Tech Mate 1000 automated immunostainer (Tucson, AZ, USA) using the standard avidin biotin peroxidase technique with the following antibodies: CD117 (Dako, Carpinteria, CA),

desmin (Biogenix, San Ramon, CA), smooth muscle actin (Novacastra, Newcastle, UK), S-100 (Thermo Scientific, Fremont, CA), vimentin (Vector, Fremont, CA), myogenin, CD34 (Neomarkers, Fremont, CA), pankeratin and myoD-1 (LabVision, Fremont, CA). In both cases, the tumors were positive for CD117 (c-Kit), Figures 2b and 3b. The prostate needle biopsy of Case 1 showed that the tumor cells were strongly and diffusely positive for CD117 (c-kit), and negative for desmin, smooth muscle actin, and S-100. In rectal biopsy of Case 2, the staining with CD117 was diffuse, but less intense than in Case 1. Tumor cells in Case 2 also showed reactivity for vimentin, very focal staining with smooth muscle actin, and rare positive cells with CD34 antibodies. No reactivity was seen with pancytokeratin, S-100, and skeletal muscle markers myogenin or myo-D1.

## Discussion

Large rectal GISTs involving or encroaching the prostate may be interpreted as primary prostatic tumors on imaging studies.<sup>6,7</sup> Prostatic enlargement as a result of GIST is very unusual. Very recently, Herawi et al reported eight cases of GIST being diagnosed on prostatic biopsy.<sup>6</sup> Only two cases have been reported in the literature as primary GIST of the prostate.<sup>8,9</sup> Interestingly, some research studies have shown that the prostate gland harbors a population of CD117-positive stromal cells analogous to the interstitial cells of Cajal, which are progenitors of gastrointestinal stromal tumors.<sup>10</sup> In both of our patients, the clinical diagnosis was very different from the pathological diagnosis. The initial clinical impression in both cases was that there were leiomyosarcomas arising from the prostate. The strong reactivity with CD117 immunostain confirmed the diagnosis of GIST in both cases. One should keep in mind, however, that CD117 expression is not specific for GISTs. Other tumors that are consistently positive for CD117 are seminoma, mastocytoma, pulmonary small cell carcinoma, and granulocytic sarcoma.<sup>11</sup> CD117 positivity should be, therefore interpreted along with the clinical history and morphologic findings.

GISTs are generally defined as immunohistochemically CD117 positive tumors, whose phenotypic properties parallel that of ICC.<sup>12</sup> GISTs have revealed mutations in exon 11 of c-Kit or less commonly in exons 9, 13, and 17. A subset of GISTs is CD117-negative and harbors mutations of the platelet derived growth factor receptor alpha (PDGF-RA). These two mutations are mutually exclusive. While c-kit tyrosine kinase inhibitor drug imatinib mesylate (Gleevec) targets both c-kit and



PDGF-RA mutations, identification of the specific mutations affecting different gene domains might be important in predicting clinical outcome and response to this target therapy. Exon 17 c-kit mutants are primarily resistant to imatinib therapy, and exon 9 mutants are less sensitive than exon 11 mutants.<sup>3</sup> While the lack of response to imatinib therapy in Case 2 suggests the possibility of c-kit mutation at exon 17, no mutation analyses was performed.

The most powerful and most studied prognostic factors of GISTs include size, location and mitotic activity expressed as number of mitoses per 50 high power fields. GISTs occur most commonly in the stomach and small intestine, but they have also been reported in other parts of the gastrointestinal tract, including the rectum and anus. Many of these tumors also express CD34 and some markers associated with smooth muscle and neural differentiation. CD34 positivity varies from 47% in small bowel to 96% to 100% in rectum and esophagus, whereas smooth muscle actin (SMA) expression shows the opposite pattern and is most frequent in the GISTs of small bowel (47%) and very infrequent in the GISTs of rectum and esophagus (10%-13%). Desmin expression is seen very infrequently. S-100 positivity is rare, but it is seen most frequently in small intestinal GISTs (15%).<sup>3</sup> The GISTs of the gut are morphologically made up of either pure or combination of spindle and epithelioid cells, and rarely pleomorphic cells. Spindled GISTs consists of uniform spindle cells forming interlacing bundles, whorls, or a storiform pattern with a variable amount of interstitial collagen. Epithelioid GISTs consists of cells, which are round in shape with eosinophilic, vacuolated, or clear cytoplasm and often arranged in sheets or nests. Rarely, a neuroendocrine type of arrangement may also be seen, mimicking a carcinoid or a paraganglioma.<sup>13</sup> The mitotic rate of these tumors is variable and a higher number usually denotes a worse prognosis.

Spindle cell proliferations of the prostate are uncommon. The differential diagnosis mainly includes postoperative spindle cell nodule, leiomyosarcoma, and specialized prostatic stromal tumors, which includes prostatic stromal proliferations of uncertain malignant potential (STUMP) and prostatic stromal sarcoma (PSS). There are other rarely reported spindle cell lesions, such as leiomyoma, phyllodes tumor, solitary fibrous tumor, carcinosarcoma, and pseudosarcomatous fibromyxoid tumor (PSFMT). Rhabdomyosarcoma is also seen in the prostate, but rarely in adults. Rarely, schwannomas arising from periprostatic nerves may be sampled on prostatic biopsy.<sup>6</sup>

Except for some distinct epidemiological and histological features present in these tumors,

immunohistochemical studies are often needed to tell these lesions apart from each other. Postoperative spindle cell nodules typically develop after transurethral resections and they may be mitotically active (up to 25 mitoses per 10 HPF), but they are typically bland-looking.<sup>11</sup> STUMP and PSS are both typically seen associated with an epithelial component and are positive for CD34, but negative for CD117. Actin can also be detected in STUMP. Leiomyosarcomas are typically positive for smooth muscle actin and may be positive for desmin.<sup>4</sup> Sarcomatoid carcinoma or carcinosarcoma of the prostate is a biphasic tumor composed of malignant epithelial and mesenchymal components, and many patients have a history of conventional prostatic adenocarcinoma treated with radiation or hormonal therapy. Epithelial markers are variably expressed in its mesenchymal component. PSFMT is a rare lesion that may involve the prostate, but is more frequently encountered in the bladder. Histologically, it is characterized by a spindle cell proliferation set in a loose, myxoid stroma with delicate vasculature and scattered inflammatory cells. In contrast with STUMP and PSS, PSFMT is not associated with a non neoplastic glandular component. They may be focally positive for smooth muscle actin, but usually negative for desmin, S-100, and cytokeratin. Solitary fibrous tumors are positive for CD34, but negative for smooth muscle markers and CD117. Rhabdomyosarcomas are typically found during the first decade of life and are most frequently of the embryonal subtype. Immunoreactivity with desmin and skeletal muscle markers myogenin and Myo-D1 is characteristic.

In summary, rectal GISTs may clinically present as a prostatic mass and should be considered in the differential diagnosis of spindle cell lesions of the prostate. Incorporating CD117 in the work-up of this type of lesions is imperative to arrive to the correct diagnosis and avoid misinterpreting rectal GISTs as primary neoplasm of the prostate. Accurate classification of these tumors is also critical for therapeutic reasons given the unique response to the tyrosine inhibitor imatinib. □

## References

1. Mazur MT, Clark HB. Gastric stromal tumors. Reappraisal of histogenesis. *Am J Surg Pathol* 1983;7:507-519.
2. Sircar K, Hewlett BR, Huizinga JD et al. Interstitial cells of Cajal as precursors of gastrointestinal stromal tumors. *Am J Surg Pathol* 1999;23:377-389.
3. Miettinen M, Lasota J. Gastrointestinal stromal tumors: review on morphology, molecular pathology, prognosis, and differential diagnosis. *Arch Pathol Lab Med* 2006;130:1466-1478.

4. Cheville J, Algaba F, Boccon-Gibod L et al. Mesenchymal tumours (Tumors of the Prostate). In: Pathology and Genetics of the Urinary System and Male Genital Organs, WHO Classification of Tumours Eble JN, Sauter G, Epstein JI, Sesterhenn IA, eds, Lyon, France: IARC 2004;209-211.
5. Ortiz-Hidalgo C, de Leon Bojorge B, Albores-Saavedra J. Stromal tumor of the gallbladder with phenotype of interstitial cells of Cajal: A previously unrecognized neoplasm. *Am J Surg Pathol* 2000;24:1420-1423.
6. Herawi M, Montgomery EA, Epstein JI. Gastrointestinal stromal tumors (GISTs) on prostate needle biopsy: A clinicopathologic study of 8 cases. *Am J Surg Pathol* 2006;30:1389-1395.
7. Kuruma H, Ao T, Suyama K et al. A case of gastrointestinal stromal tumor of rectum, difficult to differentiate from leiomyosarcoma of prostate. *Nippon Hinyokika Gakkai Zasshi* 2001;92:624-627.
8. Lee CH, Lin YH, Lin HY et al. Gastrointestinal stromal tumor of the prostate: a case report and literature review. *Hum Pathol* 2006;37:1361-1365.
9. Van der Aa F, Sciort R, Blyweert W et al. Gastrointestinal stromal tumor of the prostate. *Urol J* 2005;65:388.
10. Shafik A, Shafik I, el-Sibai O. Identification of c-kit-positive cells in the human prostate: the interstitial cells of Cajal. *Arch Androl* 2005;51:345-351.
11. Humphrey PA. Soft Tissue (Stromal) Tumors. In: Prostate Pathology. Humphrey, PA ed. Chicago, IL: ASCP Press 2003;432-441.
12. Sarlomo-Rikala M, Kovatich AJ, Barusevicius A et al. CD117: a sensitive marker for gastrointestinal stromal tumors that is more specific than CD34. *Mod Pathol* 1998;11:728-734.
13. Johnston DL, Olson JM, Benjamin DR. Gastrointestinal stromal tumor in a patient with previous neuroblastoma. *J Pediatr Hematol Oncol* 2001;23:255-256.