

Retroperitoneoscopic single-site renal pedicle lymphatic disconnection for the treatment of serious filarial chyluria

Wenli Zhuo, MD, Jinqian Chai, MD, Tingzhao Xu, MD, Weizhen Wu, MD, Shunliang Yang, MD, Jianming Tan, MD

Department of Urology, Fuzhou General Hospital, Xiamen University, Fuzhou, China

ZHUO W, CHAI J, XU T, WU W, YANG S, TAN J. Retroperitoneoscopic single-site renal pedicle lymphatic disconnection for the treatment of serious filarial chyluria. *Can J Urol* 2013;20(2):6726-6729.

Introduction: To report our preliminary techniques and experience with retroperitoneoscopic single-site renal pedicle lymphatic disconnection (RPSS-RPLD) in five patients with serious filarial chyluria.

Materials and methods: Between May 2010 and July 2011, five patients with serious filarial chyluria underwent RPSS-RPLD. In the patients, a 3 cm single incision was made between the 12th subcostal margin and posterior axillary line, and a homemade single multichannel port

using a surgical glove and three conventional trocars was placed into retroperitoneal space. The lymphatic disconnection was similar to traditional open surgery.

Results: All the operations were successfully completed without conversion to open surgery. The mean operative time was 116 (102-145) minutes. The mean blood loss was estimated to be 98 (60-190) mL. Chyluria disappeared in all patients after surgery and did not recur during the follow up period (3-14, mean 7.6 months).

Conclusion: RPSS-RPLD is safe and feasible, with favorable short term outcomes and aesthetic effect.

Key Words: renal pedicle lymphatic disconnection (RPLD), single-site, chyluria

Introduction

For patients with chyluria that is refractory to palliative treatment, bypass and disconnection surgery may be considered. Renal pedicle lymphatic disconnection (RPLD) has the most definitive therapeutic effect.¹ In most conventional open surgical procedures, a lumbar

incision is used and perinephrium and adipose capsule of kidney cut open, resulting in a heavy injury and long interval of postoperative recovery. The laparoscopic technique, with minimal invasion, less complications and rapid postoperative recovery, is being utilized more and more as the alternative surgical technique for urological disease. To further reduce the number of puncture sites and the incidence of complications, and to achieve a better aesthetic effect, laparoendoscopic single-site surgery has been adopted by urologists since 2007. In the current study, we present our preliminary techniques and experience with RPSS-RPLD in five patients with serious filarial chyluria.

Accepted for publication December 2012

Address correspondence to Dr. Jianming-Tan, Department of Urology, Fuzhou General Hospital, Xiamen University, Fuzhou, 350025, Fujian, China

Materials and methods

Patients

Five patients (4 males and 1 female) from filarial epidemic areas of Fujian, China were admitted to our hospital. The mean age of the patients was 42.3 years (range 26 to 58). All had suffered from the disease for 2.5 to 8.0 years and had typical manifestations including milky urine, weight loss, fatigue and anemia. Nearly all patients were previously diagnosed filariasis with chyluria and treated unsuccessfully with conservative therapy, such as low fat diet and renal pelvic instillation of silver nitrate. Urine chyle test using Sudan III staining was positive in all patients. Cystoscopic examination and retrograde pyelography were performed to confirm the diagnosis and to determine which side of ureter the chyluria was from, 4 cases from left ureter, 1 from right ureter.

Operative technique

Under general anesthesia and airway management, all patients were placed in the conventional flanked kidney position with the ipsilateral side elevated. A 3 cm single incision was made between the 12th subcostal margin and posterior axillary line, Figure 1. The muscular layer and the lumbodorsal fascia were divided bluntly and retroperitoneal space was separated using a finger. After that a balloon dilator was inserted into the space and 600 mL to 1000 mL sterilized normal saline was infused into the balloon to maintain the dilation of retroperitoneal space for 5 minutes. A single working channel was established with a finger, and one 5 mm and two 10 mm trocars were inserted through the channel. A medical rubber glove was used to seal the space between the incision and trocars. Generally, two

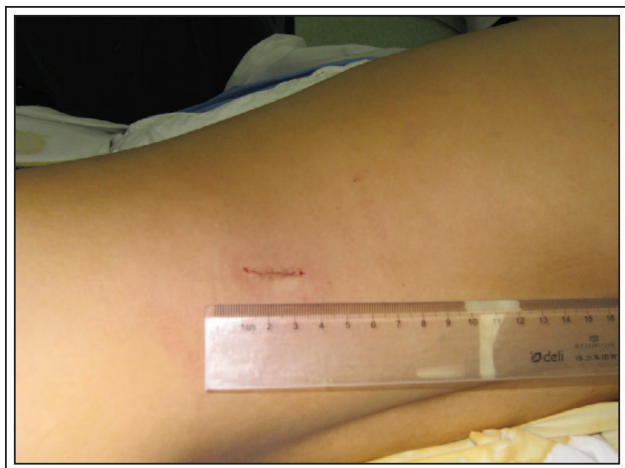

Figure 1. A 3 cm single incision image between the 12th subcostal margin and posterior axillary line.

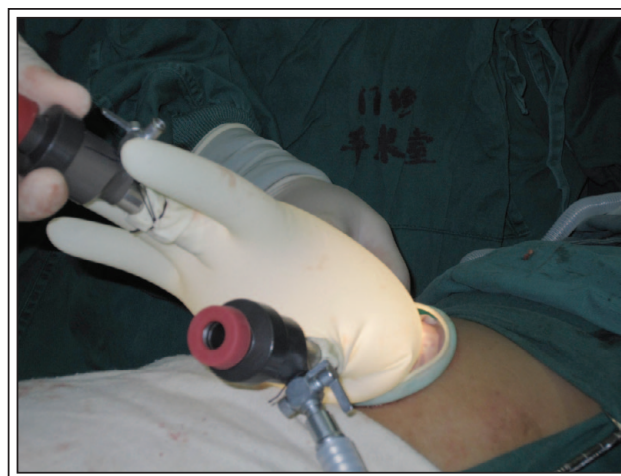

Figure 2. Overview of the homemade, single-port device.

trocars were working ports for surgical manipulation, one trocar was camera port for laparoscopic observation and CO₂ insufflation to maintain a peritoneal pressure of 13 mmHg-15 mmHg, Figure 2.

The lymphatic disconnection was similar to traditional open surgery: 1) the dorsal Gerota's fascia of the kidney was incised longitudinally close to the greater psoas muscle and adipose capsule of the kidney was separated from renal parenchymal surface using an ultrasonic knife. Then adipose tissues on the upper and lower poles and the surface of the kidney were stripped and ligated, Figure 3a; 2) the renal hilus was clearly exposed and the dilated perihilar lymphatic vessels were completely stripped. Disconnection of lymphatic vessels around renal arteries was started

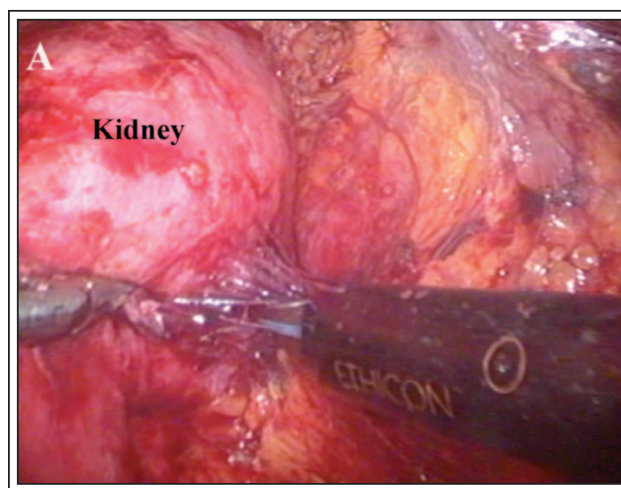


Figure 3a. Expose the renal pedicle.

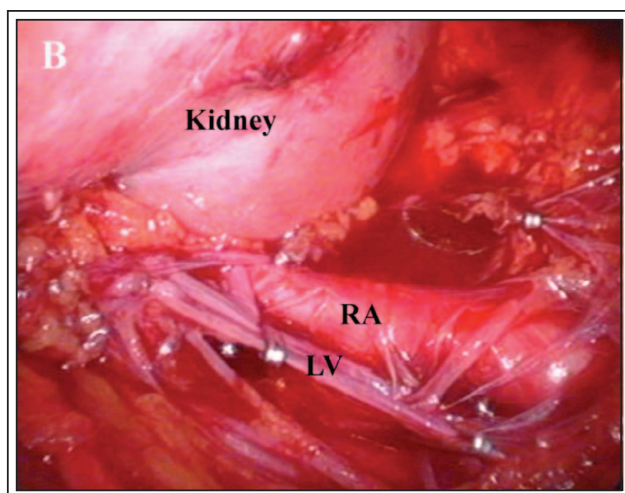


Figure 3b. Disconnection of lymphatic vessels around the renal artery.

from dorsum through the incisions of the blood vessels. Loose connective tissues containing lymphatic vessels around renal arteries were separated and ligated and then the vagina vasorum on the surface of renal arteries was incised using ultrasonic knife and ligated by titanium clips, Figure 3b. Disconnection of lymphatic vessels around renal veins was relatively easier because renal veins without obvious vaso vasorum. Lymphatic vessels were separated using suction of the surface of renal veins and then ligation by titanium clips; 3) ureterolympholysis: the ureter was isolated downward to the fork of iliac artery and lymphatic vessels around upper ureter were completely stripped, Figure 3c.

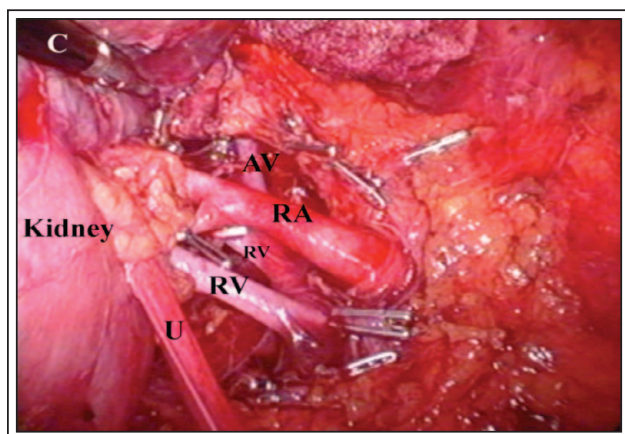


Figure 3c. Disconnection of lymphatic vessels around the renal vein and ureter.

RA = renal artery; RV = renal vein; LV = lymphatic vessels; U = ureter

Results

All of the operations were completed successfully without conversion to open surgery. The mean operative time was 116 (102-145) minutes. The estimated mean blood loss was 98 mL (range 60 mL-190 mL). The chyluria resolved in all patients immediately postoperatively. The mean hospital stay was 4.5 days (range 3-6). No complications, such as renal vessel injury, urine leakage, lymphatic leakage, or injury to adjacent organs, occurred in these patients. Chyluria did not recur during the follow up period (range 3-14 months; mean, 7.6 months).

Discussion

The etiological factors of chyluria are mainly classified as parasitic and nonparasitic, filarial infestation is the most frequent. The mechanism of filarial chyluria might be the mechanical and inflammatory injuries resulted from the filarial adult worms' colonization in human retroperitoneal lymphatic system which injure lymph vessels and their valves leading to obstruction of lymph vessels, lymphostasis, lymphoedema and lymph leakage. This usually happens in the perirenal lymph vessels and allows chyle to leak out and mix with urine, forming chyluria.² Now, radiofrequency ablation is a newly noted cause of chyluria. Chyluria is a common and asymptomatic finding in a significant proportion of patients undergoing radiofrequency ablation for renal tumors. It is important to be aware of chyluria as a possible complication of renal radiofrequency ablation. Routine urine analysis for fat should be considered, as prompt diagnosis is crucial to guide management for symptomatic patients.^{3,4}

Generally, chyluria resolves spontaneously in most patients after palliative treatment, such as bed rest and a low fat, low protein diet. Sclerotherapy, in which the renal pelvis is lavaged with a sclerosing agent, has been used for many years with occasional success.⁵ Patients with a long history of serious chyluria usually have complications, such as severe anemia and hypoproteinemia. The five patients in this group presented with emaciation, anemia, and hypoproteinemia. Therefore, surgical intervention is necessary for refractory chyluria. RPLD is thought to be the best surgical option based on a cure rate of up to 99%. Chiu and colleagues⁶ were the first to report the success of laparoscopic RPLD. In 1998, Gomella and associates⁷ reported the first successful case of retroperitoneal laparoscopic RPLD for chyluria. Further reports have demonstrated that laparoscopic RPLD via peritoneal or retroperitoneal access has the same cure rate as open surgery, and laparoscopic RPLD has advantages, such

as a magnified view, better identification of lymphatics, better anastomatic results, minimal morbidity, shorter hospital stay, excellent cosmesis, and early return to work.^{2,5,8,9}

In all five patients who underwent retroperitoneoscopic single-site procedures, gross chyluria disappeared immediately after operation without obvious intra or postoperative complications and recurrence within the follow up. We also gain the following experience from our practice: retroperitoneoscopic single-site disconnection of renal pedicle lymphatics was safe, because in a retroperitoneoscopic view, local structures appear magnified, the fine lymph vessels around the renal blood vessels and upper ureter can be clearly observed, stripped and ligated.

Conclusion

We report our initial clinical experience with RPSS-RPLD. All operations were completed successfully. RPSS-RPLD is safe and feasible for serious filarial chyluria treatment, and short term follow up has demonstrated the efficacy of RPSS-RPLD. Nevertheless, more clinical experience is needed to show whether RPSS-RPLD can replace traditional laparoscopic surgery in the treatment of patients with serious filarial chyluria. □

References

1. Puneekar SV, Kelkar AR, Prem AR, Deshmukh HL, Gavande PM. Surgical disconnection of lymphorenal communication for chyluria: A 15-year experience. *Br J Urol* 1997;80(6):858-863.
2. Jiang J, Zhu F, Jin F, Wang L. Retroperitoneoscopic renal pedicle lymphatic disconnection for chyluria. *Chin Med J (Engl)* 2003;116(11):1746-1748.
3. Wah TM. An unusual cause of chyluria after radiofrequency ablation of a renal cell carcinoma: a case report. *J Med Case Rep* 2011;5:307.
4. Kaur H, Matin SF, Javadi S, Johnson VE, Choi H, Sandler C, Ahrar K. Chyluria after radiofrequency ablation of renal tumors. *J Vasc Interv Radiol* 2011;22(7):924-927.
5. Hemal AK, Gupta NP. Retroperitoneoscopic lymphatic management of intractable chyluria. *J Urol* 2002;167(6):2473-2476.
6. Chiu AW, Chen MT, Chang LS. Laparoscopic nephrolysis for chyluria: Case report of long-term success. *J Endourol* 1995;9(4):319-322.
7. Gomella LG, Shenot P, Abdel-Meguid TA. Extraperitoneal laparoscopic nephrolysis for the treatment of chyluria. *Br J Urol* 1998;81(2):320-321.
8. Zhang X, Zhu QG, Ma X et al. Renal pedicle lymphatic disconnection for chyluria via retroperitoneoscopy and open surgery: Report of 53 cases with follow up. *J Urol* 2005;174(5):1828-1831.
9. Lan WH, Jin FS, Wang LF, Zhu FQ. A comparison of retroperitoneoscopic and open surgical renal pedicle lymphatic disconnection for the treatment of serious filarial chyluria. *Chin Med J (Engl)* 2007;120(10):932-934.