

---

# *Repetitive percutaneous epididymal sperm aspirations (PESA's) resulted in asthenospermia and significant inflammation*

Yachao Zhang, MD,<sup>1</sup> Kazim R. Chohan, PhD,<sup>2,3</sup> Steve K. Landas, MD,<sup>3,4</sup> Jay E. Reeder, PhD,<sup>4</sup> J.C. Trussell, MD<sup>4</sup>

<sup>1</sup>Department of Surgery, SUNY Upstate Medical University, Syracuse, New York, USA

<sup>2</sup>Department of Obstetrics and Gynecology, SUNY Upstate Medical University, Syracuse, New York, USA

<sup>3</sup>Department of Pathology, SUNY Upstate Medical University, Syracuse, New York, USA

<sup>4</sup>Department of Urology, SUNY Upstate Medical University, Syracuse, New York, USA

---

ZHANG Y, CHOHAN KR, LANDAS SK, REEDER JE, TRUSSELL JC. Repetitive percutaneous epididymal sperm aspirations (PESA's) resulted in asthenospermia and significant inflammation. *Can J Urol* 2014;21(5):7475-7478.

**Introduction:** In obstructive azoospermia, choosing a sperm retrieval method for intracytoplasmic sperm injection (ICSI) depends on the preference and expertise of both the urologist and the reproductive endocrinologist. Generally, a percutaneous epididymal sperm aspiration (PESA) is attempted first. Not uncommonly, multiple PESA's are necessary. This study utilizes a rat model to provide an understanding of sperm parameter and histological changes resulting from repetitive PESA procedures.

**Materials and methods:** A cohort of 30 male Wistar rats of reproductive age (68-73 days) was divided into three groups of 10 (G1-G3). All three groups underwent a left epididymal head PESA using a 25<sup>3/8</sup> gauge needle.

The untouched right epididymis acted as the control. At 14 day intervals, G2 and G3 underwent a second and third PESA respectively. Fourteen days after the final PESA, both epididymides and a 1 cm segment of both vas deferentia were harvested for sperm and histological evaluations.

**Results:** The percentage of vas specimens with a sperm count  $\geq 5 \times 10^4/\text{cc}$  was 100%, 22%, and 20% for the G1, G2, G3 PESA samples respectively. Moreover, the percentage of the vas specimens with sperm motility  $\geq 10\%$  was 90%, 22%, and 20%, respectively. Epididymal granulomas were not seen in the control side, but formed in 70%, 100%, and 80% of G1, G2, G3 PESA specimens, respectively.

**Conclusions:** In a rat model, PESA resulted in significant epididymal inflammation and a reduction in both sperm concentration and motility.

**Key Words:** PESA, repetitive, sperm parameters, histology

---

## Introduction

The choice of sperm retrieval method depends primarily on the local preference and expertise of both the physician and the in vitro fertilization (IVF) embryologist.<sup>1</sup> There is insufficient evidence to determine if the method of sperm harvesting will affect the outcome of IVF with intracytoplasmic sperm injection (ICSI).<sup>2,3</sup> Percutaneous epididymal sperm aspiration (PESA) is an increasingly popular sperm retrieval technique. Not uncommonly, multiple PESA's are performed on the same individual either because of patient's desire for more children or due to prior failed

assisted reproduction attempts. Epididymal damage is a presumed adverse effect of this method, yet there is no study defining the spectrum of damage or the effect on semen quality. This study developed a rat model to evaluate the potential epididymal damage PESA poses and its impact on sperm quantity and quality. It aims to provide clinicians with an understanding of the potential effects of repetitive PESA procedures.

## Materials and methods

### *PESA*

A total of 32 male Wistar rats of reproductive age (68-73 days old) were used. Two rats were utilized to standardize PESA, anesthesia, and necropsy techniques. The remaining 30 animals were divided into three groups of 10 (G1-G3). G1 underwent PESA once. G2 underwent PESA two times and G3 underwent PESA three times. Subsequent PESA's occurred at 14 day intervals. All rats

---

Accepted for publication August 2014

Address correspondence to Dr. J.C. Trussell, Department of Urology, SUNY Upstate Medical University, 750 East Adams Street, Syracuse, NY 13210 USA

Repetitive percutaneous epididymal sperm aspirations (PESA's) resulted in asthenospermia and significant inflammation

underwent necropsy 14 days following the last PESA, allowing for post-PESA recovery. Both epididymal heads and their ipsilateral vas deferens (1 cm segment) were harvested at the time of necropsy for semen and histological evaluation. The left epididymis was arbitrarily chosen to be the aspirated side while the right epididymis acted as the control. The procedure entailed using a 25<sup>3/8</sup> gauge needle to percutaneously aspirate the head of the epididymis while the rats were anesthetized using inhaled isofluorane. Aspirated material was immediately placed into a 1 mL 1 x PBS solution and evaluated for sperm motility and concentration. The rats were either sacrificed 14 days after the first PESA (G1) or 14 days after a subsequent (G2 or G3) PESA. Necropsy, following carbon dioxide euthanasia, was performed to harvest bilateral epididymal heads and 1 cm segment of both vas deferentia. The epididymal heads underwent histologic evaluation to discern the degree of post-PESA inflammation. Alternatively, vassal segments—downstream from the PESA-procedure(s)—were used to determine PESA-related changes to the sperm quality.

### Sperm evaluation

The 1 cm vas segment, excised during necropsy, was immersed in 1 mL of 1x PBS buffer solution and immediately evaluated for sperm motility and concentration. Sperm evaluation was performed under a phase contrast microscope using a hemocytometer.<sup>4</sup> Sperm count and percent motility was determined for each vassal segment: the left side representing PESA-related effect upon sperm quality, while the left acted as a control. The sperm count was based on sperm diffusion from either of the two cut ends of the 1 cm vassal segment.

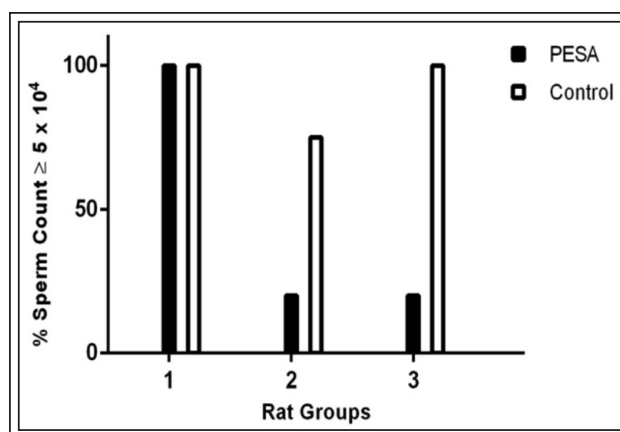
### Pathology

Both epididymal heads were excised at necropsy and fixed with buffered 4% formaldehyde for 24 hours. The tissue was subsequently fixed and then bivalved. Two slides were generated from the two cross-sectional surfaces of each specimen. The slides were stained with H&E and subsequently placed over a 1 mm x 1 mm grid paper. The surface area of the tissue slide covered by granulomas was obtained by microscopically counting the number of affected grids.

## Results

### Sperm count

Due to the variation in volume and concentration among PESA samples, direct correlation between G1-G3 cohorts was not possible. Contingency analysis was used for statistical evaluation. A sperm count of  $5 \times 10^4$ /cc (the lowest sperm concentration from the control vas deferens

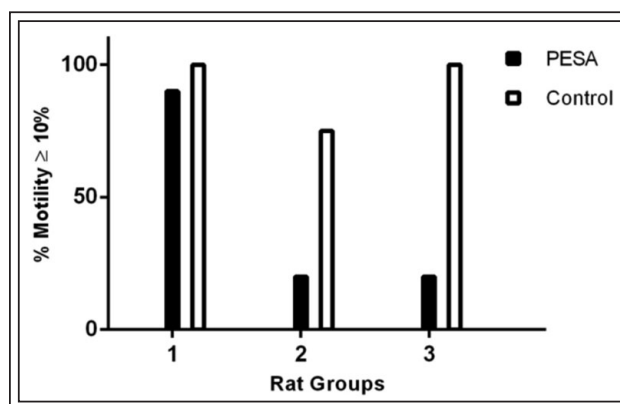


**Figure 1.** Percentage of vas deferens sperm samples with sperm count  $\geq 5 \times 10^4$ .

samples among G1 rats) was selected as a threshold. The percentages of samples in each group with sperm count greater than or equal to this threshold value were plotted, Figure 1. Among the PESA groups, 100% sperm samples in G1 were above the threshold. The percentile in G2 and G3 with a sperm count of  $5 \times 10^4$ /cc dropped to 22% and 20% respectively. Among the controls, the percentile was 100%, 71%, and 100% in G1, G2, and G3 respectively. Missing data points included three from the G2 controls and one from the G2 PESA samples. One of the rat deceased in G2 prior to reaching the end point. The other two missing data points from G2 controls were due to poor handling of the sperm samples.

### Sperm motility

There was no direct correlation between the number of PESAs and sperm motility, Table 1. Compared to controls, sperm samples from the vas deferens on the PESA side had lower sperm motility in all groups regardless the number of procedures, Figure 2.



**Figure 2.** Percentage of vas deferens sperm samples with motility  $\geq 10\%$ .

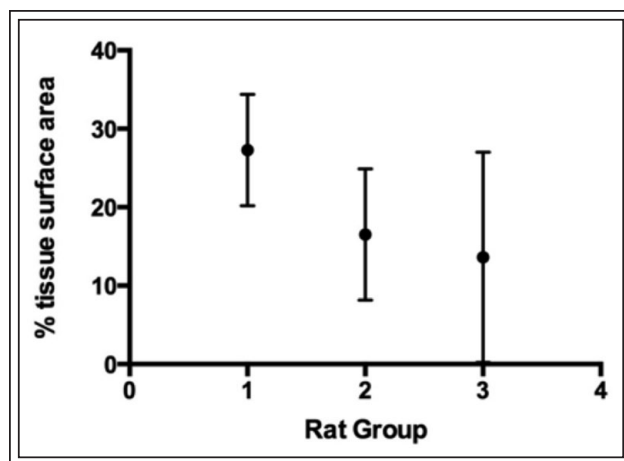
TABLE 1. Percentage of PESA samples with motility  $\geq 10\%$ 

	2 weeks after 1 <sup>st</sup> PESA	2 weeks after 2 <sup>nd</sup> PESA	2 weeks after 3 <sup>rd</sup> PESA
G1: Rats #1-10	40%		
G2: Rats # 11-20	30%	0%	
G3: Rats # 21-30	40%	0%	10%

There were three samples in G1, four samples in G2 1st PESA, two samples in G3 1st PESA, four samples in G3 2nd PESA, and eight samples in G3 3rd PESA had zero sperm counts. No correlation is found between the number of PESAs and sperm motility.

### Histological analysis of epididymal head

Sperm granulomas developed in 70%, 100% and 80% of samples in G1, G2, G3. There was a decreasing trend in average size, Figure 3. Due to the large variations in size among the samples in each group, no significant correlation between size and number of PESAs was identified.



**Figure 3.** The average granuloma size is plotted in terms of % tissue surface area. % tissue surface area is expressed as the number of grids taken up by the granuloma divided by the number of grids taken up by the entire tissue slide. 70%, 100% and 80% samples in G1, G 2, G3 developed granuloma. The average size was  $27.3 \pm 7.1$ ,  $16.5 \pm 8.4$  and  $13.6 \pm 13.4$ . Three specimens from G1 did not have granuloma, which was consistent with three animals with empty aspirations from G1. G2 has a deceased mouse; only 9 samples were accounted for. Eight out of 10 samples in G3 had granulomas. One animal from G3 had 0 sperm count from all three aspirations and one animal had 0 sperm counts in 2 out of 3 sperm samples. The error bar represents the average deviation.

### Discussion

In obstructive azoospermia, choosing a sperm retrieval method for ICSI depends on the preference and expertise of both the urologist and the reproductive endocrinologist. Generally, a PESA is attempted first. Other sperm retrieval techniques include microsurgical epididymal sperm aspiration (MESA), PESA, testicular sperm aspiration (TESA), and testicular sperm extraction (TESE). While testicular approaches may also be used for non-obstructive azoospermia, the harvested samples usually contain higher quantity of immature or immobile sperm and are typically employed when epididymal retrieval has failed. Between the two epididymal techniques, MESA allows retrieval of large quantity of sperm which is sufficient for cryopreservation of multiple vials, but requires a specialist with training in microsurgery.<sup>5,6</sup> In spite of being less reliable than an open retrieval procedure PESA is often the preferred sperm retrieval technique due to its lower cost, minimal risk and low complication rates. With ICSI success rates of 30%-40%, the need for repetitive PESA's is a realistic expectation, especially if fresh sperm is desired by the reproductive endocrinologist. There is insufficient information regarding the possible complications or decline in success with subsequent PESA punctures.<sup>7</sup> The potential drawback of repetitive PESA's (including both a lower sperm count and the potential for epididymal scarring make future sperm retrieval more difficult.<sup>5</sup> There are no prospective controlled studies that directly correlate the quantity and quality of retrieved spermatozoa to the number of PESA attempts. Although fibrosis is a possible cause of failure, there is no study found to evaluate the extent of fibrosis and its effect on the efficacy of additional PESA procedures. In this animal model, large granulomatous changes were found in the epididymis—independent of the number of PESA attempts. The various sizes and numbers of granulomas may represent the various

Repetitive percutaneous epididymal sperm aspirations (PESA's) resulted in asthenospermia and significant inflammation

responses of the tissue to inflammation. Whether it was related to variables (discussed below) or simply reflecting the possibility of various stages of recovery from the inflammatory process, long term study with a larger cohort is needed.

In a previous study,<sup>7</sup> histological changes in the epididymis of vasectomized rats were seen after multiple PESA's. There was a statistically significant difference between groups with 1 to 3 PESA attempts, with no statistical difference observed for PESA's 4 to 5. Since the vasectomy procedure (with the potential for epididymal back pressure) could impact epididymal histology and sperm quality, the study did not independently evaluate the effect of multiple PESA's. Therefore, an animal model with no prior genital tract manipulation was needed to provide for proper assessment of the PESA procedure. This study did provide significant guidance on a successful experimental design that achieves statistical significance in addition to suggesting we limit our study to three PESA procedures.<sup>7</sup>

In our study, the wide range of sperm count and motility among the aspirated samples can be attributed to several factors. For instance, the animals were the same age, but had different testicular sizes, likely indicating different reproductive potentials. The animal's sperm maturation cycles may not have been synchronous. While all procedures were done by trained residents and the urology attending, technical variations made it difficult to control for PESA precision. For these reasons, data were expressed in percentiles to reveal the relationships among the variables.

This study demonstrated that PESA's lead to epididymal inflammatory changes in addition to an adverse effect on sperm quantity and motility. In spite of immediate granuloma formation in the first PESA grouping (G1), sperm motility and concentration were not lower until the second or third PESA cohorts (G2-G3). This delayed effect could be real (it takes time for tubule scarring or inflammation to cause effect) or artificial (transport of sperm from the PESA site to the site of vassal excision may take more than 2 weeks). Whether or not these changes translate into decreased reproductive potential, require a longer term study.

Data were represented as percentages of samples above a threshold. The individual values showed increasing number of sperm count over time. This likely is the result of the Wistar rat reaching their reproductive peak during the time of this study.<sup>8</sup>

Some minor limitations in the study include difficulty with reproducible PESA technique (some punctures had "no sperm") and lack of long-term follow up to evaluate for granuloma progression

verses resolution. Furthermore, there is a disparity between bi-weekly PESA's in a rat model in contrast to human subjects where PESA's occur at much longer time intervals. Lastly, we did not specify or classify the inflammatory response nor evaluate its effect on sperm function (such as DNA damage).

## Conclusions

In a prospective rat model, PESA causes significant epididymal inflammation and a reduction in both sperm concentration and motility. □

---

## References

1. Hubbard H, Janus C, Folmer M, Kadiatu K. The management of obstructive azoospermia: AUA Best Practice Statement 2010.
2. Nicopoullos JD, Gilling-Smith C, Almeida PA, Norman-Taylor J, Grace I, Ramsay JW. Use of surgical sperm retrieval in azoospermic men: a meta-analysis. *Fertil Steril* 2004;82(3):691-701.
3. Schwarzer JU, Fiedler K, v Hertwig I et al. Sperm retrieval procedures and intracytoplasmic spermatozoa injection with epididymal and testicular sperms. *Urol Int* 2003;70(2):119-123.
4. Wang Y. Epididymal sperm count. *Curr Protoc Toxicol* 2003;16(6):16.6.1-16.6.5.
5. Schlegel PN, Berkeley AS, Goldstein M et al. Epididymal micropuncture with in vitro fertilization and oocyte micromanipulation for the treatment of unreconstructable obstructive azoospermia. *Fertil Steril* 1994;61(5):895-901.
6. Sheynkin YR, Ye Z, Menendez S, Liotta D, Veeck LL, Schlegel P. Controlled comparison of percutaneous and microsurgical sperm retrieval in men with obstructive azoospermia. *Hum Reprod* 1998;13(11):3086-3089.
7. Saade RD, Neves PA, Glina S, D'Ancona CA, Dambros M, Lúcio MA. Quantitative (stereological) and qualitative study of rat epididymis after vasectomy and percutaneous epididymal sperm aspiration. *J Urol* 2008;179(1):381-384.
8. Saksena SK, Lau IF, Chang MC. Age dependent changes in the sperm population and fertility in the male rat. *Exp Aging Res* 1979;5(4):373-381.