

---

# Prostate cancer polar localization on core biopsy predicts pathologic stage

Patrick J. Hensley, MD,<sup>1,2</sup> Lisa R. Bailey, MD,<sup>1</sup> Matthew S. Purdom, MD,<sup>2</sup> Daniel L. Davenport, PhD,<sup>3</sup> Stephen E. Strup, MD<sup>1</sup>

<sup>1</sup>Department of Urology, University of Kentucky, Lexington, Kentucky, USA

<sup>2</sup>Department of Pathology, University of Kentucky, Lexington, Kentucky, USA

<sup>3</sup>Department of Surgery, University of Kentucky, Lexington, Kentucky, USA

---

HENSLEY PJ, BAILEY LR, PURDOM MS, DAVENPORT DL, STRUP ES. Prostate cancer polar localization on core biopsy predicts pathologic stage. *Can J Urol* 2016;23(6):8551-8556.

**Introduction:** This study investigated the polar sub-localization of prostate cancer on needle core biopsy ("polar" defined as tumor  $\leq 1$  mm from the tissue polar edge) as a predictor of extraprostatic extension.

**Materials and methods:** Histologic sections from 58 patients who underwent preoperative prostate biopsy and radical prostatectomy at the University of Kentucky from 2006 to 2013 were evaluated. Patients were retrospectively case matched based on pathologic stage (pT2 versus pT3/4) using biopsy Gleason grade and prostate-specific antigen. Histologic sections of needle core biopsies were analyzed for polar involvement. The location of polar involvement was correlated to the presence of extraprostatic extension on final prostatectomy pathology.

**Results:** Average percentage of total polar cores was predictive of extraprostatic extension on final prostatectomy,

particularly in the prostatic apex and base ( $p = 0.029$  and  $0.006$ , respectively). Higher grade tumors were identified at the pole in the high stage cohort ( $p = 0.032$ ). Total percent polar involvement had the greatest sensitivity and specificity for predicting extraprostatic extension when directly compared to previously described histologic parameters (percent greatest involvement of a single core, length of greatest involvement of a single core, presence of perineural invasion, presence of bilateral gland involvement, and percent total positive core involvement). The location of polar involvement on needle core biopsy was also predictive of the precise location of extraprostatic extension on final prostatectomy pathology (Chi-square  $p < .001$ , negative predictive value  $> 70\%$  in all prostate sextants).

**Conclusions:** These data suggest the use of biopsy polar core involvement as a valuable histologic predictor of increased pathologic stage.

**Key Words:** prostate cancer, biopsy, Gleason grade, extraprostatic extension, pathologic stage

---

## Introduction

Needle core biopsy of the prostate is an essential component to the diagnosis and preoperative assessment of prostate cancer. Clinicians have traditionally used an integrated analysis of prostate-

specific antigen (PSA) value, clinical stage and biopsy Gleason grade to predict extraprostatic extension (associated with advanced staged disease and metastasis). This assessment may influence the selection of patients who are surgical candidates and the extent of operative resection. Identification of additional predictive characteristics of extraprostatic extension in core biopsy may enhance the sensitivity of this preoperative assessment to aide in better therapeutic outcomes for patients.

The prostate is conventionally biopsied transrectally, producing cores of prostatic tissue from the bilateral prostate apex, mid-gland and base. Investigations have

---

Accepted for publication September 2016

Address correspondence to Dr. Stephen E. Strup, Department of Urology, University of Kentucky, 800 Rose Street, Suite MS283, Lexington, KY 40536 USA

previously identified histologic characteristics in core biopsies that correlate with more aggressive disease: Gleason grade,<sup>1-3</sup> number of involved cores,<sup>1-6</sup> average percent involvement of each positive core,<sup>1,4,5,7</sup> location of positive core,<sup>2,3</sup> length of tumor in positive core,<sup>2,3</sup> presence of perineural invasion,<sup>8</sup> and cancer presence bilaterally.<sup>4</sup> To our knowledge, there has never been an investigation of cancer location within the biopsy core as a predictor of extraprostatic extension. Furthermore, there has never been a case-matched series comparing the predictive utility of needle core biopsy parameters when controlling for biopsy Gleason grade and PSA.

## Materials and methods

### *Patient population and case matching*

Patients who underwent both preoperative needle core biopsy of the prostate and radical prostatectomy at the University of Kentucky Medical Center from January 1, 2006 to January 1, 2013 were eligible for inclusion. After obtaining Institutional Review Board approval a specimen database maintained by the Department of Pathology was retrospectively interrogated to compile lists of eligible patients divided into pT3/pT4 tumors and pT2 tumors based on final pathologic staging. Each T3/T4 case was matched with a T2 case based on two criteria: 1) identical biopsy Gleason grade and 2) pre-biopsy maximum PSA of < 10, 10-20 or > 20 ng/mL. Matching was achieved by first identifying a T3/T4 case and assessing compatibility with T2 cases listed in chronological order (resulting in preferential selection of older T2 cases).

### *Pathologic specimen analysis*

Biopsy slides were retrieved from the Department of Pathology archive. Only histologic sections with the greatest cross-sectional area were analyzed. Sections were reviewed using standard light microscopy for the following parameters: total number of cores involved and sub-location (apex, mid, base) of positive cores, location of tumor within each positive core, percent involvement of the core with greatest tumor burden, measured tumor length in the core with greatest involvement, and presence of perineural invasion (PNI). The location of the tumor within each core was categorized as one of the following: polar (tumor ≤ 1 mm from one or both tissue polar edges) or non-polar (tumor > 1 mm from both poles). Cores with clearly recognizable rectal or periprostatic adipose tissues were orientable and only tumor ≤ 1 mm of the adjacent polar extent of prostatic parenchyma (posterior aspect) were considered true polar cores. Measured tumor length and percent involvement of each core was evaluated by measuring

contiguous tumor length and total core length. If tumor was identified at a polar edge, the greatest Gleason grade present within this pole was recorded. Extent and location of extraprostatic extension (EPE) were analyzed by retrospective slide review of the radical prostatectomy specimen. Extent was recorded as "focal" or "established" using both the Epstein criteria (focal defined as few extraprostatic glands and established defined as anything more extensive than focal)<sup>9</sup> and the criteria described in Wheeler et al (focal defined as EPE in one high power field in ≤ 2 sections and established as anything more extensive than focal).<sup>10</sup>

### *Definitive pathology and clinical parameters*

Final pathologic reports of prostatectomy specimens were reviewed for TNM stage, Gleason grade and margin status. Clinical demographics and outcomes data, including age, race, biochemical recurrence (BCR; defined as PSA > 0.2 ng/mL or any rise in PSA resulting in treatment) and need for adjuvant therapy were obtained with retrospective review of the electronic medical record and records obtain from the Kentucky Cancer Registry.

### *Statistical analysis*

The receiver operating characteristics curve was graphed for each predictor of EPE and the area under the curve (AUC) was calculated. Predictors were compared between stage using Fisher's exact, Spearman's Rho or Mann-Whitney U tests, as appropriate. Sensitivity, specificity, positive predictive value and negative predictive value were calculated for polar involvement at each biopsy sextant relative to extraprostatic extension at that sextant. Significance was set at  $p < .05$ . All statistical calculations were performed with SPSS version 22 (IBM Corp., Armonk, NY, USA).

## Results

### *Polar involvement predicts EPE on final prostatectomy*

Patients with pT3/pT4 prostatic adenocarcinoma with known EPE were retrospectively case matched with patients with pT2 cancer (organ confined disease) based on: 1) identical biopsy Gleason grade, controlling for tumor aggressiveness; 2) preoperative PSA, controlling for tumor volume. Patient characteristics between the two groups are listed in Table 1. There are no statistical differences between clinical characteristics, prostate cancer risk factors or needle core biopsy length except for median follow up.

Ultrasound-guided needle core biopsies of the prostate were reviewed for polar involvement,

TABLE 1. Patient information. Clinical characteristics of the case matched patient groups

	T2	T3/4	p value
Number of patients: n	29	29	
Race: n (%)			0.565
Caucasian	28 (87.5%)	28 (87.5%)	
African American	4 (12.5%)	3 (9.4%)	
Other	0	1 (3.1%)	
Age: mean $\pm$ SD	59 $\pm$ 7	60 $\pm$ 7	0.456
Preoperative PSA: mean (ng/mL) $\pm$ SD	8.2 $\pm$ 4.4	9.3 $\pm$ 7.3	0.486
Follow up (median years)	4.24	5.96	0.011
Average positive core length (mm) $\pm$ SD	10.0 $\pm$ 2.0	9.1 $\pm$ 2.2	0.139

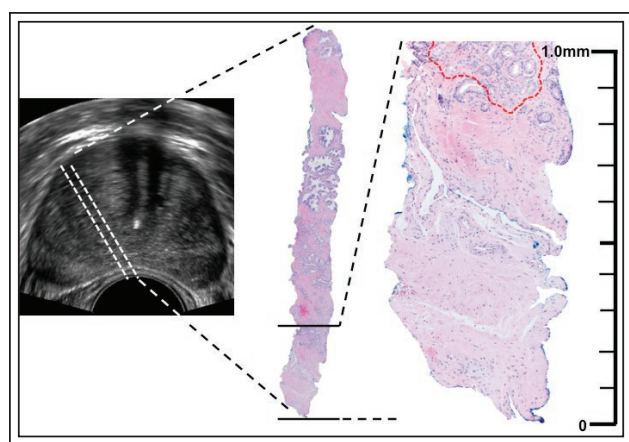
Figure 1. Average percentage of total polar cores was predictive of EPE and increased tumor stage on final prostatectomy, Table 2 and Figure 2. This was particularly significant in the prostatic apex and base ( $p = 0.029$  and  $0.006$ , respectively). Additionally, despite controlling for biopsy Gleason grade through case matching, higher grade tumors were identified at the pole in the high stage cohort ( $p = 0.032$ ).

Previously described characteristics predictive of EPE on needle core biopsy were validated, with percent greatest involvement of a single core and percentage of cores involved by tumor being significantly associated with EPE ( $p = 0.006$  and  $0.009$ , respectively; Table 2). The presence of perineural invasion, measured length of greatest involvement and presence of bilateral core

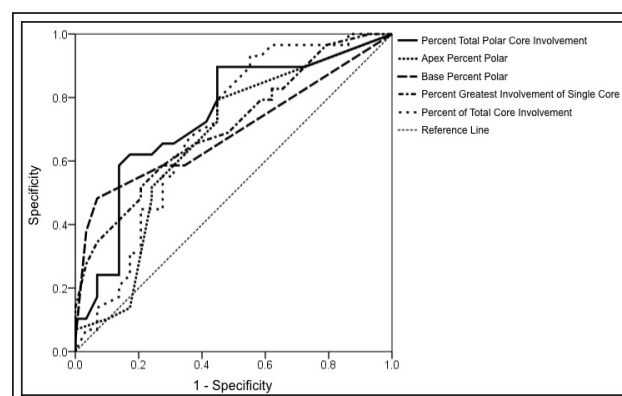
involvement were not significantly associated with EPE. Histologic parameters were directly compared for ability to predict tumor stage. Of the characteristics studied, total polar involvement had the greatest sensitivity and specificity for predicting EPE (area under the receiver operator curve 0.784).

#### *Polar involvement on biopsy as a predictor of location and extent of EPE on prostatectomy*

Preoperative understanding of the precise location of EPE would be of important clinical utility relative to nerve sparing approaches and surgical margins. Radical prostatectomy slides from the T3/4 cases were retrospectively reviewed for the location of EPE based on prostate sextant, and this location was compared to the location of polar involvement of the needle core biopsy. At least one biopsy core with polar involvement from 4 out of the 6 prostatic sextants was significantly associated with EPE in that respective sextant, Table 3a.



**Figure 1.** Defining “polar involvement.” Transrectal ultrasound-guided needle core biopsies of the prostate preferentially inked from the prostatic apex, mid-gland and base were reviewed for polar involvement, defined as cancer located  $\leq 1$  mm from the core tip.



**Figure 2.** Receiver operating characteristic (ROC) of predictors of EPE.

**TABLE 2. Histologic predictors of EPE. Biopsies were evaluated for polar involvement in the prostatic apex, mid-gland and base. Results were compared with known histologic characteristics predictive of EPE**

	T2 (n = 29)	T3/T4 (n = 29)	p value	Area under curve
% of total polar cores in prostatic tertile				
Apex	21.6%	37.3%	0.029	0.662
Mid	16.2%	26.4%	0.106	0.617
Base	9.3%	25.9%	0.006	0.693
Total	15.1%	30.3%	0.001	0.784
Gleason grade at pole			0.032 <sup>a</sup>	0.661
3	10 cases (47.6%)	4 cases (15.4%)		
4	9 cases (42.9%)	18 cases (69.2%)		
5	2 cases (9.5%)	4 cases (15.4%)		
% greatest involvement of single core	43.8%	64.0%	0.006	0.707
Presence of perineural invasion	37.5%	56.3%	0.137	0.621
Length of core with greatest involvement	4.55 mm	6.1 mm	0.143	0.611
Bilateral core involvement	12 cases (41.4%)	11 cases (37.9%)	1.000	0.517
% total core involvement	34.6%	48.4%	0.009	0.699

<sup>a</sup>Spearman's rho non-parametric correlation = 0.314, p = 0.032.

With regards to all biopsy locations, at least one polar core from a respective sextant significantly predicted the precise location of EPE (Chi-square p < .001). The negative predictive value for the absence of polar involvement correlating with the absence of EPE on prostatectomy was ≥ 70% in all sextants.

Further correlation of polar involvement with the

extent of EPE in the prostatectomy specimen was achieved by retrospective review of prostatectomy slides. EPE was defined as "established" or "focal" based on two established grading systems for EPE.<sup>9,10</sup> Although polar involvement could accurately predict the location of EPE, it could not predict its' extent using either criteria, Table 3b.

**TABLE 3. Polar involvement predicts location, but not extent, of EPE. Correlation of polar involvement to EPE relative to biopsy sextant (A). Data represents at least one positive polar core in the respective sextant. Correlation of polar involvement to extent of EPE based on two established criteria (B)**

#### A

Sextant	Sensitivity	Specificity	PPV	NPV	p value
Left apex	0.66	0.65	18%	94%	0.475
Left mid	0.60	0.84	66%	80%	0.032
Left base	0.41	0.94	83%	70%	0.032
Right apex	0.82	0.67	60%	86%	0.017
Right mid	0.67	0.86	83%	71%	0.013
Right base	0.58	0.71	58%	71%	0.164
All sextants	0.62	0.77	60%	78%	0.000

#### B

	Focal	Established	p value
Epstein et al criteria	25.1%	31.4%	0.499
Wheeler et al criteria	33.4%	29.5%	0.660

PPV = positive predictive value; NPV = negative predictive value



**TABLE 4. Polar involvement as a predictor of clinical outcome. Percent polar involvement respective to the presence or absence of individual clinical outcomes. Biochemical recurrence defined as PSA > 0.2 ng/mL or any rise in PSA resulting in treatment**

	Yes	No	p value
Prostate cancer-specific survival	22.4% (n = 56)	32.4% (n = 2)	0.458
Biochemical recurrence	29.8% (n = 19)	19.3% (n = 39)	0.042
Adjuvant radiation	33.4% (n = 13)	19.6% (n = 45)	0.017
Positive margin	23.2% (n = 21)	22.4% (n = 37)	0.880

### *Polar involvement predicts clinically significant disease*

There was a significantly higher percentage of polar involvement in those patients who achieved biochemical recurrence and were treated with adjuvant radiation therapy, Table 4. Although similar trends were associated with metastasis and prostate cancer-specific survival, the patient cohort was too small to detect statistical significance. Notably, although polar involvement predicts EPE, it is not associated with margin status.

## Discussion

Accurately predicting EPE through critical evaluation of the preoperative needle core biopsy is of high clinical utility in selection of surgical candidates and the extent of operative resection. This study represents the first to independently evaluate the potential of cancer sub-localization on the needle core biopsy pole as a predictor for EPE, and to compare this with previously described histologic parameters on needle core biopsy predictive of EPE in a case matched series. Stage T3/4 patients with known EPE were matched with T2 patients based on PSA and biopsy Gleason grade, controlling for tumor volume<sup>11</sup> and tumor aggressiveness,<sup>12</sup> respectively.

Results of this study indicate that polar localization (tumor  $\leq$  1mm from the needle core tip) is predictive of EPE on definitive pathology. Furthermore, polar involvement outperformed previously identified predictors of EPE, including presence of bilaterality, length of tumor involvement, maximum percent involvement of a single core, presence of perineural invasion, and percent of positive cores. Poor concordance between tumor localization on biopsy and final pathology is thought to result from tumor multifocality and the oblique nature of the TRUS biopsy relative to the posterior prostatic plane.<sup>13</sup> Our study suggests significant positive correlation of the location of polar involvement with the precise location of EPE on prostatectomy with high specificity and

negative predictive values. Preoperative localization of EPE could prove influential in intraoperative decision making, including nerve sparing approaches and preservation of surgical margins. The posterior prostatic margin of the biopsy is a fixed point independent of the depth or angle of the biopsy and may more reproducibly predict sub-localization of the tumor on the prostatectomy specimen. Additionally, despite matching of cases for identical biopsy Gleason grade, higher grade tumors were localized in the pole of those patients with EPE. This has prognostic value as higher grade tumors localized to sites of EPE and positive surgical margins is associated with disease progression.<sup>14,15</sup>

Other methods of predicting EPE have included imaging modalities such as multiparametric magnetic resonance imaging (MRI), which has accurately predicted T3 disease in 72% of patients.<sup>16</sup> Advancements in the field, including restriction spectrum imaging (RSI-MRI), have resulted in increased sensitivity.<sup>17</sup> The relative disadvantage to identifying and localizing EPE based on polar involvement is its restricted application to surveying the posterior prostate via TRUS biopsy. However, the majority of EPE derived from the peripheral zone occurs in the postero-lateral prostate.<sup>18</sup> This contrasts with anterior EPE originating from the transition zone which cannot be evaluated on TRUS biopsy using the polar approach. Furthermore, the polar extent of the perineal biopsy is localized towards the prostatic apex, which has historically challenged pathologists to diagnose EPE based on ambiguity of histologic landmarks in the apex.<sup>15</sup>

Limitations to this study include small sample size and limited clinical follow up. Polar involvement was statistically associated with BCR, but outcomes including disease-specific survival and metastasis failed to reach statistical significance due to the limited sample size. Additionally, stage was not controlled for when calculating these outcomes data. Another limitation to the study of polar involvement is the unorientable nature of the majority of needle

core biopsies and the potential for core fragments to confound interpretation of the polar edge. Further studies are necessary to confirm the specificity and utility of this histologic parameter and may include prospectively marking the posterior aspect of the core to orient the pathologist.

## Conclusions

Prostate cancer localization to the pole of the needle core biopsy is predictive of the presence and location of EPE on final prostatectomy. The measurement of polar involvement is a simple histologic tool that can be reported by pathologists to aide in clinical decision making regarding pre-operative patient risk stratification and operative planning regarding nerve sparing approaches to radical prostatectomy. □

## References

1. Tsuzuki T, Hernandez DJ, Aydin H, Trock B, Walsh PC, Epstein JI. Prediction of extraprostatic extension in the neurovascular bundle based on prostate needle biopsy pathology, serum prostate specific antigen and digital rectal examination. *J Urol* 2005;173(2):450-453.
2. Naya Y, Slaton JW, Troncso P, Okihara K, Babaian RJ. Tumor length and location of cancer on biopsy predict for side specific extraprostatic cancer extension. *J Urol* 2004;171(3):1093-1097.
3. Nakanishi H, Troncso P, Babaian RJ. Prediction of extraprostatic extension in men with biopsy Gleason score of 8 or greater. *J Urol* 2008;180(6):2441-2445.
4. Gao X, Mohideen N, Flanigan RC, Waters WB, Wojcik EM, Leman CR. The extent of biopsy involvement as an independent predictor of extraprostatic extension and surgical margin status in low risk prostate cancer: implications for treatment selection. *J Urol* 2000;164(6):1982-1986.
5. Dong F, Jones JS, Stephenson AJ, Magi-Galluzzi C, Reuther AM, Klein EA. Prostate cancer volume at biopsy predicts clinically significant upgrading. *J Urol* 2008;179(3):896-900.
6. Hong SK, Han BK, Lee ST et al. Prediction of Gleason score upgrading in low-risk prostate cancers diagnosed via multi (> or = 12)-core prostate biopsy. *World J Urol* 2009;27(2):271-276.
7. Ravary V, Chastang C, Toubanc M, Boccon-Gibod L, Delmas V, Boccon-Gibod L. Percentage of cancer on biopsy cores accurately predicts extracapsular extension and biochemical relapse after radical prostatectomy for T1-T2 prostate cancer. *Eur Urol* 2000;37(4):449-455.
8. Bismar TA, Lewis JS Jr, Vollmer RT, Humphrey PA. Multiple measures of carcinoma extent versus perineural invasion in prostate needle biopsy tissue in prediction of pathologic stage in a screening population. *Am J Surg Pathol* 2003;27(4):432-40.
9. Epstein J, Carmichael MJ, Pizov G, Walsh PC. Influence of capsular penetration on progression following radical prostatectomy: a study of 196 cases with long-term follow up. *J Urol* 1993;150(1):135-141.
10. Wheeler TM, Dilliogluligil O, Kattan MW et al. Clinical and pathological significance of the level and extent of capsular invasion in clinical stage T1-2 prostate cancer. *Hum Pathol* 1998; 29(8):856-862.
11. Cantiello F, Russo GI, Ferro M et al. Prognostic accuracy of Prostate Health Index and urinary Prostate Cancer Antigen 3 in predicting pathologic features after radical prostatectomy. *Urol Oncol* 2015;33(4):15-23.
12. Berman DM, Epstein JI. When is prostate cancer really cancer? *Urol Clin North Am* 2014;41(2):339-346.
13. Schulte RT, Wood DP, Daignault S, Shah RB, Wei JT. Utility of extended pattern prostate biopsies for tumor localization: pathologic correlations after radical prostatectomy. *Cancer* 2008;113(7):1559-1565.
14. Cheng L, Darson MF, Bergstralh EJ, Slezak J, Myers RP, Bostwick DG. Correlation of margin status and extraprostatic extension with progression of prostate carcinoma. *Cancer* 1999;86(9):1775-1782.
15. Brimo F, Partin AW, Epstein J. Tumor grade at margins of resection in radical prostatectomy specimens is an independent predictor of prognosis. *Urology* 2010;76(5):1206-1209.
16. Rud E, Klotz D, Rennesund K et al. Preoperative magnetic resonance imaging for detecting uni- and bilateral extraprostatic disease in patients with prostate cancer. *World J Urol* 2014;33(7):1015-1021.
17. Rakow-Penner RA, White NS, Parsons JK et al. Novel technique for characterizing prostate cancer utilizing MRI restriction spectrum imaging: proof of principle and initial clinical experience with extraprostatic extension. *Prostate Cancer Prostatic Dis* 2015;18(1):81-85.
18. Magi-Galluzzi C, Evans AJ, Delahunt B et al. International Society of Urological Pathology (ISUP) Consensus Conference on Handling and Staging of Radical Prostatectomy Specimens. Working group 3: extraprostatic extension, lymphovascular invasion and locally advanced disease. *Mod Pathol* 2011;24(1): 26-38.